

BLS Review

1999 Objectives

There are no 1999 objectives for this chapter.

1985 Objectives

- 1.6.62** Demonstrate effective cardiopulmonary resuscitation. (p 1549)
- *S1.9.24** Demonstrate on an adult mannequin, the techniques for single and two-person CPR according to American Heart Association standards. (p 1567)
- *S1.9.25** Demonstrate on an infant mannequin, the technique for infant CPR according to American Heart Association standards. (p 1572)

*Indicates optional.

Additional Objectives†

Cognitive

1. Identify the need for basic life support, including the urgency surrounding its rapid application. (p 1546, 1549)
2. List the EMT-I's responsibilities in beginning and terminating CPR. (p 1549)
3. Describe the proper way to position an adult patient to receive basic life support. (p 1551)
4. Describe the proper way to position an infant and child to receive basic life support. (p 1551)
5. Describe the three techniques for opening the airway in infants, children, and adults. (p 1551)
6. List the steps in providing artificial ventilation in infants, children, and adults. (p 1560)
7. Describe how gastric distention occurs. (p 1562)
8. Define the recovery position. (p 1563)
9. Describe infectious disease issues related to rescue breathing. (p 1560)
10. List the steps in providing chest compressions in an adult. (p 1564)
11. List the steps in providing chest compressions in an infant and child. (p 1571)
12. List the steps in providing one-rescuer CPR in an infant, child, and adult. (p 1567)
13. List the steps in providing two-rescuer CPR in an infant, child, and adult. (p 1567)

14. Distinguish foreign body airway obstruction from other conditions that cause respiratory failure. (p 1554, 1558)
15. Distinguish a complete airway obstruction from a partial airway obstruction. (p 1554, 1557)
16. Describe the steps in removing a foreign body obstruction in an infant, child, and adult. (p 1555)

Affective

17. Recognize and respect the feelings of the patient and family during basic life support. (p 1550)
18. Explain the urgency surrounding the rapid initiation of basic life support measures. (p 1546)
19. Explain the EMT-I's responsibilities in starting and terminating CPR. (p 1549)
20. Explain the rationale for removing a foreign body obstruction. (p 1554)

Psychomotor

21. Demonstrate how to position the patient to open the airway. (p 1551)
22. Demonstrate how to perform the head tilt-chin lift maneuver in infants, children, and adults. (p 1552)
23. Demonstrate how to perform the jaw-thrust and modified jaw-thrust maneuvers in infants, children, and adults. (p 1554)
24. Demonstrate how to place a patient in the recovery position. (p 1563)
25. Demonstrate how to perform chest compressions in an adult. (p 1564)
26. Demonstrate how to perform chest compressions in an infant and child. (p 1571)
27. Demonstrate how to perform one-rescuer CPR in an infant, child, and adult. (p 1567)
28. Demonstrate how to perform two-rescuer CPR in an infant, child, and adult. (p 1567)
29. Demonstrate how to remove a foreign body obstruction in an infant, child, and adult. (p 1555, 1558)

†All of these objectives are noncurriculum objectives.

You are the Provider

You and your partner are dispatched to 1300 Blossom Lane for an unconscious male, unknown cause. A few minutes later, the dispatcher informs you that "CPR is in progress."

1. Given the initial nature of the call, what would be a good idea?
2. After the dispatcher notifies you that CPR is in progress, what should you do to prepare?

BLS Review

The principles of basic life support were introduced in 1960. Since that time, the specific techniques have been reviewed and revised every 5 to 6 years. The updated guidelines are published in *JAMA*. The most recent revision occurred as a result of the 2005 Conference on Cardiopulmonary Resuscitation and Emergency Cardiac Care. The guidelines in this chapter follow those proposed at the 2005 conference. Note that the 1994 EMT-Basic National Standard Curriculum requires basic life support (BLS) as a prerequisite to the EMT-I course; it is presented here as a review.

This chapter begins with a definition and general discussion of BLS. The next sections describe methods for opening and maintaining an airway, providing artificial ventilation to a person who is not breathing, providing artificial circulation to a person with no pulse, and removing a foreign body airway obstruction. Each of these sections is followed by a review of the changes in technique that are necessary to treat infants and children. A discussion of the methods of preventing the transmission of infectious diseases during CPR is provided in Chapter 2.

Elements of BLS

Basic life support (BLS) is noninvasive (not involving penetration of the body, such as with surgery or a hypodermic needle) emergency lifesaving care that is used



EMT-I Safety

While your chances of contracting a disease during CPR training or actual CPR on a patient are very low, common sense and OSHA (Occupational Safety and Health Administration) guidelines both demand that you take reasonable precautions to prevent unnecessary exposure to infectious disease. Using standard precautions makes the risk *extremely* low; then you don't have to be anxious about practicing and performing the skill.

to treat medical conditions, including airway obstruction, respiratory arrest, and cardiac arrest. This care focuses on what is often termed the ABCs: airway (obstruction), breathing (respiratory arrest), and circulation (cardiac arrest or severe bleeding)

Figure 39-1 ▶. BLS follows a specific sequence for adults and for infants and children **Table 39-1** ▶. Ideally, only seconds should pass between the time you recognize that a patient needs BLS and the start of treatment. Remember, brain cells die every second that they are deprived of oxygen. Permanent brain damage may occur if the brain is without oxygen for 4 to 6 minutes. After 6 minutes without oxygen, some brain damage is almost certain **Figure 39-2** ▶.

If a patient is not breathing well or at all, you may simply need to open the airway. Very often, this will help the patient breathe normally again. However, if the patient has no pulse, you must combine artificial ventilation with artificial circulation. If breathing stops before the heart stops, the patient will have enough oxygen in the lungs to stay alive for several minutes. But when a patient goes into cardiac arrest first, the heart and brain stop receiving oxygen immediately.

Cardiopulmonary resuscitation (CPR) is used to establish artificial ventilation and circulation in a patient who is not breathing and has no pulse. The steps for CPR include the following:

1. Opening the airway
2. Restoring breathing by means of rescue breathing (mouth-to-mouth ventilation, mouth-to-nose ventilation, or using mechanical devices)
3. Restoring circulation by means of chest compressions to circulate blood through the body

To maximize survival, you must be able to easily identify a patient who is in respiratory and/or cardiac arrest and begin treatment with BLS measures immediately **Figure 39-3** ▶.

Technology

Interactivities

Vocabulary Explorer

Anatomy Review

Web Links

Online Review Manual

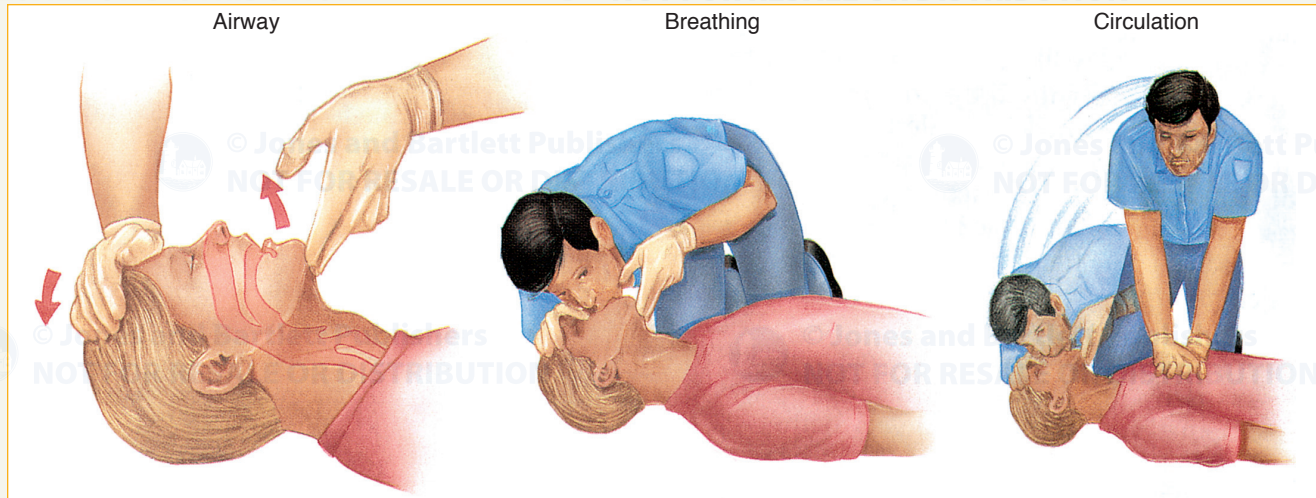


Figure 39-1 The ABCs of basic life support are airway, breathing, and circulation.

TABLE 39-1 Review of Pediatric BLS Procedures

Procedure	Infants (younger than 1 y)	Children (1 y to onset of puberty) ¹
Airway	Head tilt–chin lift; jaw thrust if spinal injury is suspected	Head tilt–chin lift; jaw thrust if spinal injury is suspected
Breathing		
Initial breaths	2 breaths with duration of 1 second each with enough volume to produce chest rise	2 breaths with duration of 1 second each with enough volume to produce chest rise
Subsequent breaths	1 breath every 3 to 5 seconds; 12 to 20 breaths/min	1 breath every 3 to 5 seconds; 12 to 20 breaths/min
Circulation		
Pulse check	Brachial artery	Carotid or femoral artery
Compression area	Just below the nipple line	In the center of the chest, in between the nipples
Compression width	2 fingers or 2-thumb hands-encircling technique	Heel of one or both hands
Compression depth	$\frac{1}{3}$ to $\frac{1}{2}$ the depth of the chest	$\frac{1}{3}$ to $\frac{1}{2}$ the depth of the chest
Compression rate	100/min	100/min
Ratio of compressions to ventilations	30:2 (one rescuer); 15:2 (two rescuers) ²	30:2 (one rescuer); 15:2 (two rescuers) ²
Foreign body obstruction	Conscious: back slaps and chest thrusts Unconscious: CPR	Conscious: abdominal thrusts Unconscious: CPR

¹ Onset of puberty is approximately 12-14 years of age, as defined by secondary characteristics (eg, breast development in girls and armpit hair in boys).

² Pause compressions to deliver ventilations.

You are the Provider

Part 2

Five minutes later, you arrive at the scene to find a hysterical woman standing at the front door. She tells you that her husband is in the back bedroom, and he's not breathing. As you enter the bedroom, you see an elderly male who is lying in bed. A dog is in the bed next to him, growling and barking at you.

3. What is your first priority?
4. What information do you need to obtain from the patient's wife?

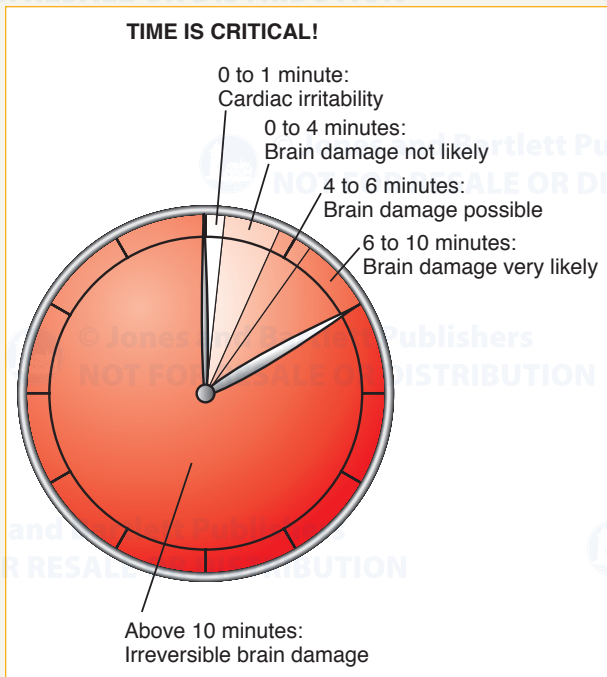


Figure 39-2 Time is critical for patients who are not breathing. If the brain is deprived of oxygen for 4 to 6 minutes, brain damage is likely to occur.

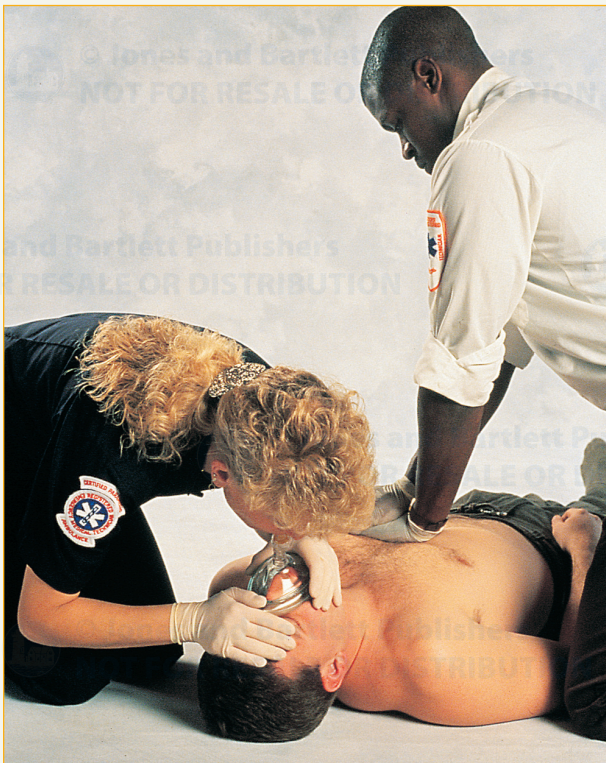


Figure 39-3 You must quickly identify patients in respiratory and/or cardiac arrest so that BLS measures can begin immediately.

Rescue breathing can be given by one or two EMT-Is or EMT-Bs, by first responders, or by trained bystanders. It does not require any equipment; however, you should use a barrier device when performing rescue breathing. Rescue breathing delivers exhaled gas from you to the patient. This gas contains 16% oxygen, which is sufficient to maintain the patient's life. Once you determine that the patient needs BLS, you should begin rescue breathing immediately, along with efforts to support the circulation and correct cardiac problems.

BLS differs from **advanced life support (ALS)**, which involves advanced lifesaving procedures, such as cardiac monitoring, administration of intravenous fluids and medications, and the use of advanced airway adjuncts. However, when done correctly, BLS can maintain life for a short time until ALS measures can be started. In some cases, such as choking, near drowning, or lightning injuries, early BLS measures may be all that is needed to restore a patient's pulse and breathing. Of course, these patients also require transport to the hospital for evaluation.

BLS measures are only as effective as the person who is performing them. Your skills will be very good immediately after training. However, as time goes on, your skills will deteriorate unless you practice them regularly.

Automated External Defibrillation

Most out-of-hospital cardiac arrests occur as the result of a sudden cardiac rhythm disturbance (dysrhythmia), such as ventricular fibrillation (V-fib) or pulseless ventricular tachycardia (V-tach). According to the American Heart Association, early defibrillation is the link in the chain of survival that is most likely to improve survival rates. For each minute the patient remains in V-fib or pulseless V-tach, there is a 7% to 10% smaller chance of survival.

The automated external defibrillator (AED) should be attached to any adult nontraumatic cardiac arrest patient as soon as possible; defibrillation, if indicated, must be performed without delay. The AED is not indicated for children less than 1 year of age, regardless of the cause of their cardiac arrest.

The AED's simple design makes it easy for EMT-Is, EMT-Bs, first responders, and laypersons to use; very little training is required.

If you witness the patient's cardiac arrest, begin CPR and apply the AED as soon as it is available. However, if the patient's cardiac arrest was not witnessed by you, especially if the call-to-arrival interval is greater than 5 minutes, the American Heart Association recommends that you perform 5 cycles (about 2 minutes) of CPR before applying the AED. The rationale for this is that the heart is more likely to respond to defibrillation within the first few minutes of the onset of ventricular fibrillation. If the arrest interval is prolonged, however, metabolic waste products accumulate within the heart, energy stores are rapidly depleted, and the chance of successful defibrillation is reduced. Therefore, a 2-minute period of CPR before applying the AED in patients with prolonged (> 5 minutes) cardiac arrest can "prime the pump," thus restoring oxygen to the heart, removing metabolic waste products, and increasing the chance of successful defibrillation.

AEDs can safely be used in patients older than 1 year of age. If using the AED on a child between 1 and 8 years of age, you should use pediatric-sized pads and a dose-attenuating system (energy reducer). However, if these are unavailable, you should use an adult AED. Refer to Chapter 20 for complete information regarding the AED, including proper use, safety considerations, and the AED algorithm.

Assessing the Need for BLS

As always, begin by surveying the scene. Is it safe? How many patients are there? What is your initial impression of the patients? Are there bystanders who may have information? Do you suspect trauma? If you were dis-

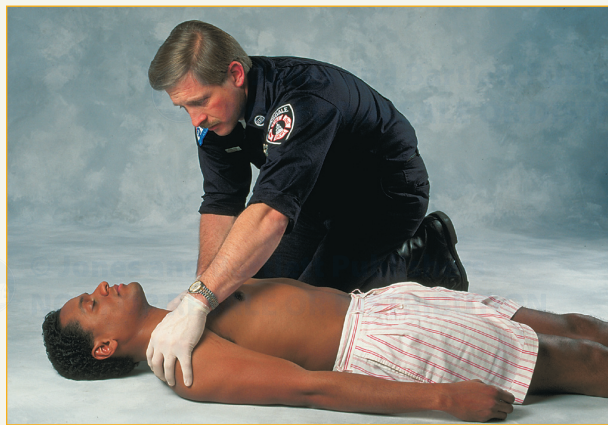

Figure 39-4 Assess airway, breathing, and circulation in an unconscious patient by first attempting to rouse the patient.

patched to the scene, does the dispatch information match what you are seeing?

Because of the urgent need to start CPR in a pulseless, nonbreathing patient, you must complete an initial assessment as soon as possible, evaluating the patient's ABCs. The first step is determining unresponsiveness (Figure 39-4). Clearly, a patient who is conscious does not need CPR; a person who is unresponsive may need CPR, depending on further assessment findings.

You may also suspect the presence of a cervical spine injury. If so, you must protect the spinal cord from further injury as you perform CPR. If there is even a remote possibility of this type of injury, you should begin taking appropriate precautions during the initial assessment.

The basic principles of BLS are the same for infants, children, and adults. For the purposes of BLS, anyone younger than 1 year is considered an infant. A child is between 1 year of age and the onset of puberty (12 to 14 years of age). Adulthood is from onset of puberty and older. Children vary in size. Some small children may best be treated as infants and some larger children as adults. There are two basic differences in providing CPR for infants, children, and adults. The first is that the emergencies in which infants and children require CPR have different underlying causes. The second is that there are anatomic differences among adults, children, and infants. These differences include smaller airways in infants and children than in adults.

Although cardiac arrest in adults usually occurs before respiratory arrest, the reverse is true in infants and children. In most cases, cardiac arrest in children results from respiratory arrest. If untreated, respiratory arrest will quickly lead to cardiac arrest and death. Respiratory arrest in infants and children has a variety of causes, including aspiration of foreign bodies into the airway, such as parts of hot dogs, peanuts, candy, or small toys; airway infections, such as croup and epiglottitis; near-drowning incidents or electrocution; and sudden infant death syndrome (also known as SIDS).

When to Start and Stop BLS

As an EMT-I, it is your responsibility to start CPR in virtually all patients who are in cardiac arrest. There are only two general exceptions to the rule.

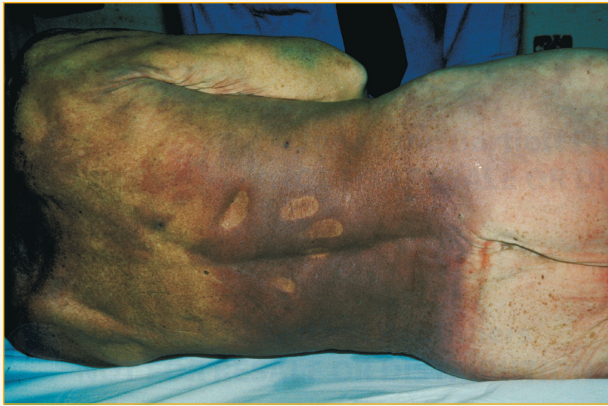

Figure 39-5 Dependent lividity is an obvious sign of death, caused by blood settling to the areas of the body not in firm contact with the ground. The lividity in this figure is seen as purple discoloration of the back, except in areas that are in firm contact with the ground (scapula and buttock).

Documentation Tips

Correct handling of situations when you choose not to start CPR on a patient in cardiac arrest begins with compliance with protocols and ends with detailed documentation. In particular, record physical exam signs that led to your decision, and make reference to the protocol that states these signs as a reason not to start. If extenuating circumstances such as entrapment physically prevent resuscitation attempts, record the conditions thoroughly. These decisions occasionally give rise to questions that can often be put to rest immediately by reference to a well-written report.

First, you should not start CPR if the patient has obvious signs of death. Signs of obvious death include an absence of a pulse and breathing, along with any one of the following:

- Rigor mortis, or stiffening of the body after death
- Dependent lividity (livor mortis), a discoloration of the skin due to pooling of blood **(Figure 39-5 ▲)**
- Putrefaction or decomposition of the body
- Evidence of a nonsurvivable injury, such as decapitation, dismemberment, or burned beyond recognition.

Rigor mortis and dependent lividity develop after a patient has been dead for a long period.

Second, you should not start CPR if the patient and his or her physician have previously agreed on

Figure 39-6 You should not start CPR if the patient and his or her physician have previously agreed on DNR or no-CPR orders. Learn your local protocols for treating terminally ill patients.

DNR (do not resuscitate) or no-CPR orders **(Figure 39-6 ▲)**. This may apply only to situations in which the patient is known to be in the terminal stage of an incurable disease. In this situation, CPR serves only to prolong the patient's death. However, this can be a complicated issue. Advance directives, such as living wills, may express the patient's wishes; however, these documents may not be readily producible by the patient's family or caregiver. In such cases, the safest course is to assume that an emergency exists and begin CPR under the rule of implied consent and contact medical control for further guidance. Conversely, if a valid DNR document or living will is produced, resuscitative efforts may be withheld. Learn your local protocols and the standards in your system for treating terminally ill patients. Some EMS systems have computer notes on patients who are preregistered with the system. These notes usually specify the amount and extent of treatment that are desired. Other states have specific EMS DNR forms that allow EMS providers to withhold care in situations where the patient, family, and physician have agreed in advance that such a course is most appropriate. It is critical that you understand your local protocols and are aware of the specific restrictions these advance directives imply.

In all other cases, you should begin CPR on anyone who is in cardiac arrest. It is usually impossible to know how long the patient has been without oxygen to the brain and vital organs. Factors such as air temperature and the basic health of the patient's tissues and organs can affect their ability to survive. There-



Pediatric Needs

Opening the airway in an infant or child is done by using the same techniques that are used for an adult. However, because a child's neck is so flexible, the head tilt-chin lift maneuver should be modified so that as you tilt the head back, you are moving it only into the neutral position or a slightly extended position **Figure 39-7** ▶. You may also use the jaw-thrust maneuver. In fact, this is the best method to use if you suspect a spinal injury in a child. If a second rescuer is present, he or she should immobilize the child's cervical spine.

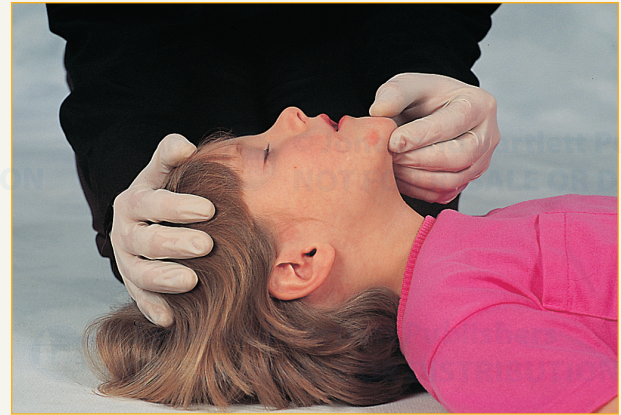

Figure 39-7 The head tilt-chin lift maneuver on a child is slightly modified in that as you tilt the head back, you move it only into the neutral position or a slightly extended position.

fore, most legal advisers recommend that, when in doubt, you should always give too much care rather than too little. You should always start CPR if any doubt exists.

You are not responsible for making the decision to stop CPR. Once you begin CPR in the field, you must continue until one of the following events occurs:

- **S** The patient **starts** breathing and has a pulse.
- **T** The patient is **transferred** to another person who is trained in BLS, to ALS-trained personnel, or to another emergency medical responder.
- **O** You are **out** of strength or too tired to continue.
- **P** A **physician** who is present or providing online medical direction assumes responsibility for the patient and gives direction to discontinue CPR.

“Out of strength” does not mean merely weary; it means no longer physically able to perform CPR. In short, CPR should always be continued until the patient's care is transferred to a physician or higher medical authority in the field. In some cases, your medical director or a designated medical control physician may order you to stop CPR on the basis of the patient's condition.

Every EMS system should have clear standing orders or protocols that provide guidelines for starting and stopping CPR. Your medical director and your system's legal adviser should agree on these protocols, which should be closely administered and reviewed by your medical director.

Positioning the Patient

The next step in providing CPR is to position the patient to ensure that the airway is open. For CPR to be effective, the patient must be lying supine on a firm surface, with enough clear space around the patient for two rescuers to perform CPR. You will need to reposition any patient who is “crumpled up” or lying face down. The few seconds that you spend to position the patient properly will greatly improve the delivery and effectiveness of CPR.

Follow the steps in **Skill Drill 39-1** ▶ to reposition an unconscious adult patient for airway management:

- 1. Kneel beside the patient.** You and your partner must be far enough away so that the patient, when rolled toward you, does not come to rest in your lap (**Step 1**).
- 2. First EMT-I: Place your hands** behind the patient's back, head, and neck to protect the cervical spine if you suspect spinal injury. **Second EMT-I:** Place your hands on the distant shoulder and the hip (**Step 2**).
- 3. Second EMT-I: Turn the patient toward you** by pulling on the distant shoulder and the hip. **First EMT-I:** Control the head and neck so that they move as a unit with the rest of the torso. This single motion will allow the head, neck, and back to stay in the same vertical plane and will minimize aggravation of any spinal injury (**Step 3**).
- 4. First EMT-I: Place the patient in a supine position**, with the legs straight and both arms at the sides (**Step 4**).

Positioning the Patient

39-1



- 1** Kneel beside the patient, leaving room to roll the patient toward you.



- 2** Grasp the patient, stabilizing the cervical spine if needed.



- 3** Move the head and neck as a unit with the torso as your partner pulls on the distant shoulder and hip.



- 4** Move the patient to a supine position with legs straight and arms at the sides.

If possible, log roll the patient onto a long backboard as you are positioning him or her for CPR. This device will provide support during transport and emergency department care. Once the patient is properly positioned, you can easily assess airway, breathing, circulation, and the need for defibrillation and start CPR if necessary.

Opening the Airway in Adults

Without an open airway, rescue breathing will not be effective. There are two techniques for opening the airway in adults: the head tilt–chin lift maneuver and the jaw-thrust maneuver.

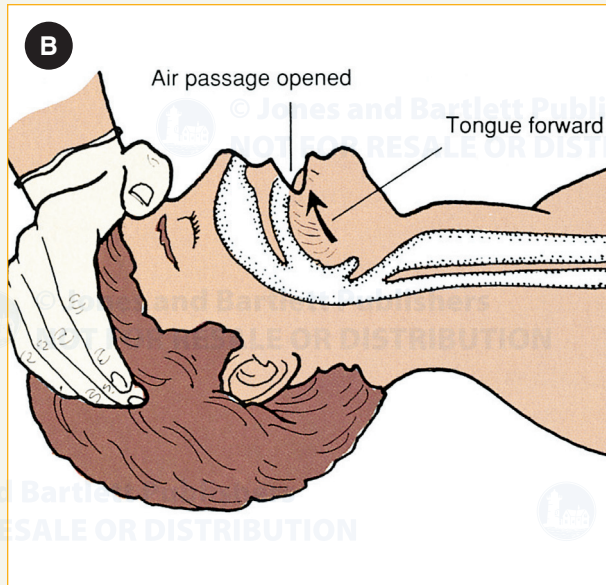
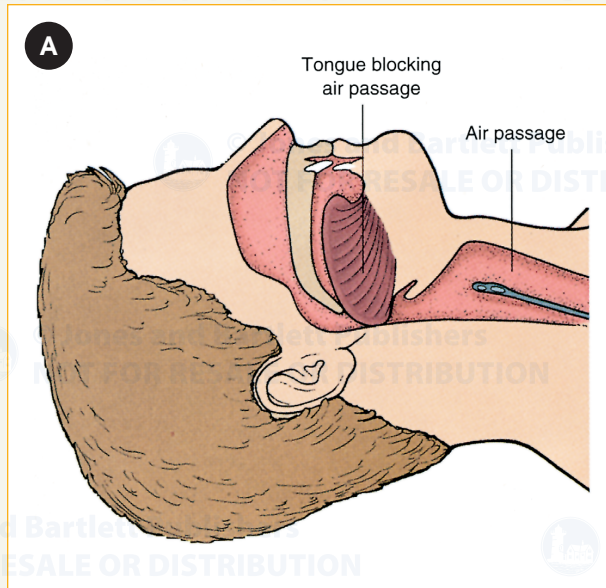


Figure 39-8 **A.** Relaxation of the tongue back into the throat causes airway obstruction. **B.** The head tilt-chin lift maneuver combines two movements of opening the airway.

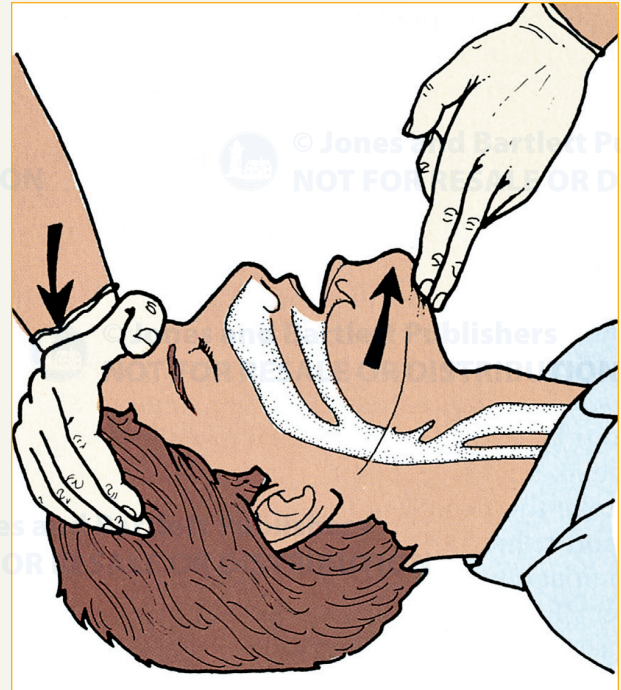


Figure 39-9 To perform the head tilt-chin lift maneuver, place one hand on the patient's forehead, and apply firm backward pressure with your palm to tilt the head back. Next, place the tips of the fingers of your other hand under the lower jaw near the bony part of the chin. Lift the chin forward, bringing the entire lower jaw with it, helping to tilt the head back.

Head Tilt–Chin Lift Maneuver

Opening the airway to relieve an obstruction caused by relaxation of the tongue can often be accomplished quickly and easily with the **head tilt–chin lift maneuver** (Figure 39-8 ◀). In patients who have not sustained trauma, this simple maneuver is sometimes all that is required for the patient to resume breathing. If the patient has any foreign material or vomitus in the mouth, you should quickly remove it. Wipe out any liquid materials from the mouth with a piece of cloth held by your index and middle fingers; use your hooked

You are the Provider

Part 3

You confirm that the patient is unresponsive, and you and your partner move the man down to the floor. As you open his airway, copious amounts of vomitus come from his mouth. While you are managing his airway, your partner checks for a carotid pulse and finds none.

5. Why should you move the patient, and what should you do if you cannot?
6. What should you do to manage his airway, and what should be the next step your partner performs?

index finger to remove any solid material. You should perform the head tilt–chin lift maneuver in an adult in the following way **Figure 39-9** ◀:

1. Make sure the patient is supine. Kneel close beside the patient.
2. Place one hand on the patient's forehead, and apply firm backward pressure with your palm to tilt the patient's head back. This extension of the neck will move the tongue forward, away from the back of the throat, and will clear the airway if the tongue is blocking it.
3. Place the tips of the fingers of your other hand under the lower jaw near the bony part of the chin. Do not compress the soft tissue under the chin, as this would block the airway.
4. Lift the chin forward, bringing the entire lower jaw with it, helping to tilt the head back. Do not use your thumb to lift the chin. Lift so that the teeth are nearly brought together, but avoid closing the mouth completely.

The chin lift has the added advantage of holding loose dentures in place, making obstruction by the lips less likely. Performing ventilation is much easier when dentures are in place. However, dentures that do not stay in place should be removed. Partial dentures (plates) may come loose as a result of an accident or as you are providing care, so check these periodically.

Jaw-Thrust Maneuver

The head tilt–chin lift maneuver is effective for opening the airway in most patients. In cases of suspected spinal injury, you want to minimize movement of the patient's neck. In this case, perform a **jaw-thrust maneuver**. To perform a jaw-thrust maneuver, place your fingers behind the angles of the patient's lower jaw and then move the jaw forward. Keep the head in a neutral position as you move the jaw forward and open the mouth. If the patient's mouth remains closed, you can use your thumbs to pull the patient's lower lip down, to allow breathing. You can also easily apply a face mask or other barrier device with both hands while performing the jaw thrust.

Perform the jaw-thrust maneuver as follows

Figure 39-10 ▶:

1. Kneel above the patient's head. Place your index or middle finger behind the angle of the patient's lower jaw on both sides, and forcefully move the jaw forward without manipulating the patient's neck.

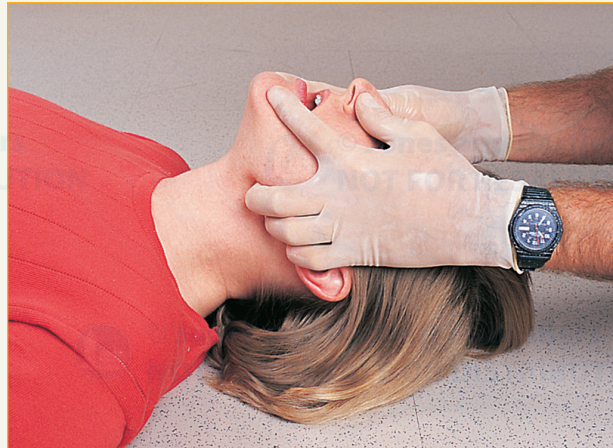

Figure 39-10 To perform the jaw-thrust maneuver, maintain the head in neutral alignment and use your index and long fingers to thrust the jaw forward.

2. Use your thumbs to open the mouth to allow breathing.
3. The nose can be sealed with your cheek when providing rescue breathing using the jaw-thrust maneuver.

Foreign Body Airway Obstruction in Adults

Airway obstruction may be caused by many things, including relaxation of the throat muscles in an unconscious patient, vomited or regurgitated stomach contents, a blood clot, damaged tissue after an injury, dentures, or a foreign body in the airway. Occasionally, a large foreign body will be aspirated and block the upper airway.

Large objects that cannot be removed from the airway with suction, such as loose dentures, large pieces of vomited food, or blood clots, should be swept forward and out with your gloved index finger. Suctioning can then be used as needed to keep the airway clear of thinner secretions, such as blood, vomitus, and mucus.

Recognizing Foreign Body Obstruction

Sudden airway obstruction by a foreign body in an adult usually occurs during a meal. In a child, it usually occurs during mealtime or at play. Children commonly choke on

peanuts, large bits of hot dog, or small toys. If the foreign body is not removed quickly, the lungs will use up their oxygen supply; unconsciousness and death will follow. Your treatment will be based on the cause of the obstruction. Therefore, you must learn to tell the difference between airway problems caused by a foreign body obstruction and those due to respiratory failure or arrest.

Conscious Patients

Sudden airway obstruction is usually easy to recognize in someone who is eating or has just finished eating. The person is suddenly unable to speak or cough, grasps his or her throat, turns cyanotic, and makes exaggerated efforts to breathe. Either air is not moving into and out of the airway or the air movement is so slight that it is not detectable. At first, the patient will be conscious and able to clearly indicate the nature of the problem. Ask the patient, "Are you choking?" The patient will usually answer by nodding yes. Alternatively, he or she may use the universal sign to indicate airway blockage

Figure 39-11 ▶

Unconscious Patients

When you encounter an unconscious patient, your first step is to determine whether he or she is breathing and has a pulse. The unconsciousness may be due to airway obstruction, cardiac arrest, or a number of other problems. Remember that you must first clear the patient's airway before addressing other problems, such as cardiac arrest. You must first ensure an open and unobstructed airway before checking for a pulse.

You should suspect an airway obstruction if the standard maneuvers to open the airway and ventilate the lungs are not effective. If you feel resistance when ventilating the patient or pressure builds up in your mouth, the patient probably has some type of obstruction.

Removing a Foreign Body Obstruction in Patients Over 1 Year of Age

The manual maneuver recommended for removing a foreign body airway obstruction in the conscious adult and child is the abdominal-thrust maneuver (the Heimlich maneuver). This technique creates an artificial cough by causing a sudden increase in intrathoracic pressure when thrusts are applied to the subdiaphragmatic region; it is a very effective method for removing a foreign body that is obstructing the airway.

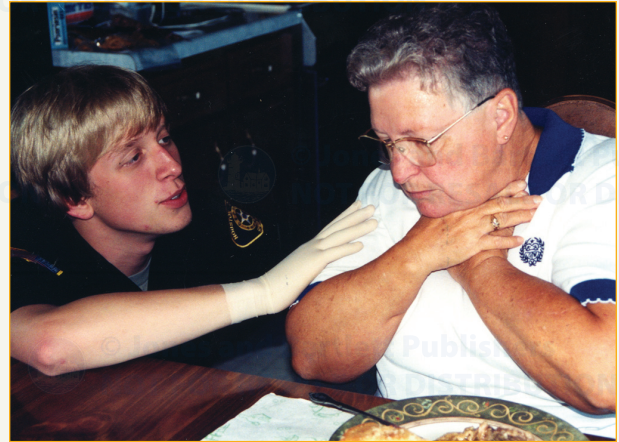

Figure 39-11 Hands at the throat are the universal sign to indicate choking.

Conscious Patients

Abdominal-thrust Maneuver

The **abdominal-thrust maneuver**, also called the Heimlich maneuver, is the preferred way to dislodge and force food or other material from the throat of a choking victim. Residual air, which is always present in the lungs, is compressed upward and used to expel the object. In conscious patients with a complete airway obstruction, you should repeat abdominal thrusts until the foreign body is expelled or the patient becomes unconscious. Each thrust should be deliberate, with the intent of relieving the obstruction.

To perform abdominal thrusts on the conscious adult **Figure 39-12** ▶, use the following technique:

1. Stand behind the patient, and wrap your arms around his or her waist.
2. Make a fist with one hand; grasp the fist with the other hand. Place the thumb side of the fist against the patient's abdomen, just above the umbilicus and well below the xiphoid.
3. Press your fist into the patient's abdomen with a quick inward and upward thrust.
4. Continue abdominal thrusts until the object is expelled from the airway or the patient becomes unconscious.

Chest Thrusts

You can perform the abdominal-thrust maneuver safely on all adults and children. However, you should preferentially use chest thrusts for women in advanced stages of pregnancy and patients who are very obese.



Figure 39-12 The abdominal-thrust maneuver in a conscious adult patient. Stand behind the patient, and wrap your arms around his or her waist. Press your fists into the patient's abdomen, and deliver quick inward and upward thrusts.



Figure 39-13 Removal of foreign body obstruction in the conscious adult patient using chest thrusts. Stand behind the patient and wrap your arms around the patient's chest. Place the thumb side of one fist against the chest while holding your fist with the other hand. Press your fists into the patient's chest with backwards thrusts.

To perform chest thrusts on the conscious adult, use the following technique (Figure 39-13):

1. Stand behind the patient with your arms directly under the patient's armpits, and wrap your arms around the patient's chest.
2. Make a fist with one hand; grasp the fist with the other hand. Place the thumb side of the fist against the patient's sternum, avoiding the xiphoid process and the edges of the rib cage.
3. Press your fist into the patient's chest with backward thrusts until the object is expelled or the patient becomes unconscious.

If the patient becomes unconscious, you should begin CPR (Figure 39-14).

Unconscious Patients

The patient with an airway obstruction may become unconscious and require additional care. Knowing that this patient had an obstruction will prompt the EMT-I to open the airway and look inside before completing the additional steps of resuscitation.

When a choking victim is found unconscious, it is unlikely that the EMT-I will know what caused the problem. Begin the steps of CPR by determining unrespon-

siveness, opening the airway, and attempting ventilation. If the first ventilation does not produce visible chest rise, reposition the head and reattempt to ventilate (Figure 39-15). If both breaths fail to produce visible chest rise, perform 30 chest compressions and then open the airway and look in the mouth. If an object is visible, attempt to remove it. *Never perform blind finger sweeps on any patient; doing so may push the obstruction further into the airway.* After opening the airway and looking inside the mouth, reattempt to ventilate the patient. Continue performing chest compressions, opening the airway and looking inside the mouth, and attempting to ventilate until the airway is clear or you reach definitive care.

Mild Airway Obstruction

Patients with a mild (partial) airway obstruction are able to exchange adequate amounts of air, but still have signs of respiratory distress. Breathing may be noisy; however, the patient usually has a strong, effective cough. Leave these patients alone! Your main concern is to pre-

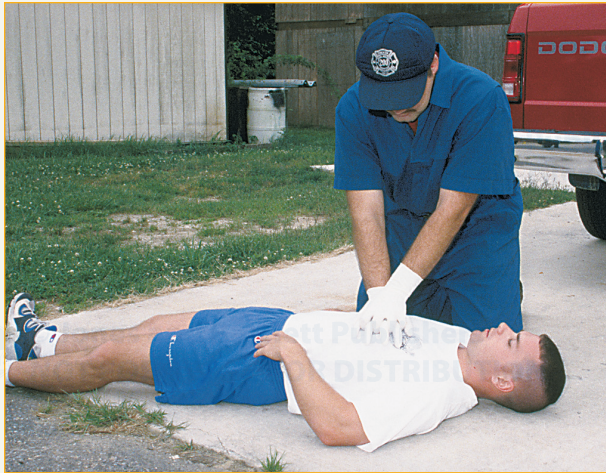

Figure 39-14 Perform chest compressions (CPR) on an unconscious patient with a severe airway obstruction.

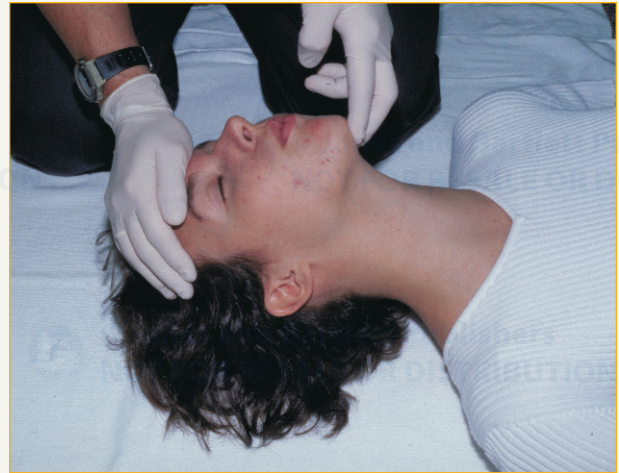


Figure 39-15 The head tilt-chin lift maneuver is a simple technique for opening the airway in a patient without a suspected cervical spine injury.

vent a mild airway obstruction from becoming a severe airway obstruction. The abdominal thrust is not indicated in patients with a mild airway obstruction.

For the patient with a mild airway obstruction, you should first encourage him or her to cough or to continue coughing if they are already doing so. Do not interfere with the patient's own attempts to expel the foreign body. Instead, give 100% oxygen with a nonrebreathing mask and provide prompt transport to the hospital. Closely monitor the patient and observe for signs of a severe airway obstruction (weak or absent cough, decreasing level of consciousness, cyanosis).

Foreign Body Obstruction in Infants and Children

Airway obstruction is a common problem in infants and children and usually is caused by a foreign body or an infection, such as croup or epiglottitis, resulting in swelling and narrowing of the airway. You should try to identify the cause of the obstruction as soon as possible. In patients who have signs and symptoms of an airway infection, you should not waste time trying to dislodge a foreign body. The child needs 100% oxygen with a nonrebreathing mask and immediate transport to the emergency department.

A previously healthy child who is eating or playing with small toys or an infant who is crawling about the house and who suddenly has difficulty breathing has

probably aspirated a foreign body. As in adults, foreign bodies may cause a mild or severe airway obstruction.

With a mild airway obstruction, the patient can cough forcefully, although there may be wheezing between coughs. As long as the patient can breathe, cough, or talk, you should not interfere with his or her own attempts to expel the foreign body. As with the adult, encourage the child to continue coughing. Administer 100% oxygen with a nonrebreathing mask (if tolerated) and provide transport to the hospital.

You should intervene only if signs of a severe airway obstruction develop, such as a weak, ineffective cough, cyanosis, absent air movement, or a decreasing level of consciousness. If this occurs, stand or kneel behind the child and provide abdominal thrusts until the object is expelled or the child becomes unconscious

Figure 39-16 ▶.

Removing a Foreign Body Airway Obstruction

Conscious Infants

The abdominal-thrust maneuver might injure the liver or other abdominal organs in an infant. Therefore, use the following technique to remove a foreign body in an infant **Figure 39-17** ▶:

1. Place one hand on the infant's back and neck and the other on his or her chest, jaws, and face, holding the jaw firmly to support the head at a

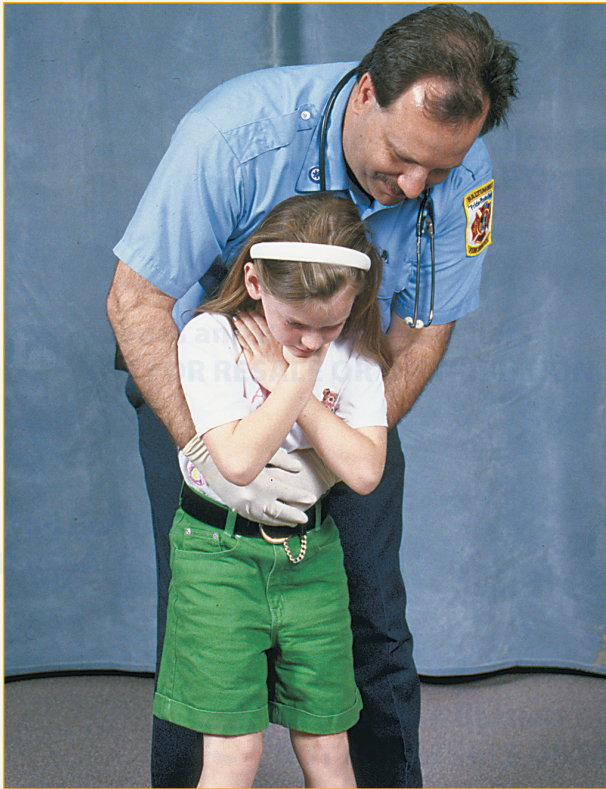


Figure 39-16 Stand behind the child, place your arms around the armpits, and wrap your arms around the patient's abdomen and chest. Press your fists into the patient's abdomen, and provide quick, upward thrusts.

level lower than the trunk. This sandwiches the infant between your hands and arms. Your forearm should rest on your thigh to support the infant.

2. Deliver five quick back slaps between the shoulder blades, using the heel of your hand.
3. Next, turn the infant face up, making sure that you support the head and neck. Hold the infant in a supine position on your thigh, with the head slightly lower than the trunk.
4. Give five quick chest thrusts on the sternum in the same manner as for CPR, except at a slightly slower rate. If the infant is large or your hands are small, you might need to place the infant on your lap to deliver the chest thrusts.

Unconscious Infants

Begin CPR with one extra step: Look inside the airway each time before ventilating and remove the object if seen.

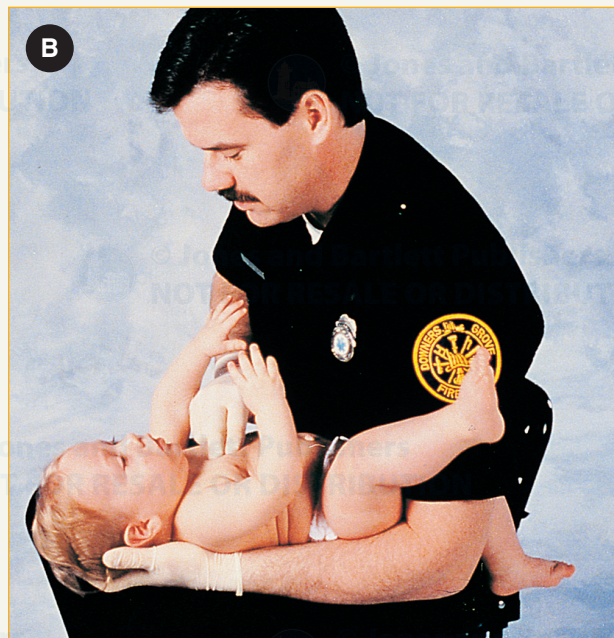
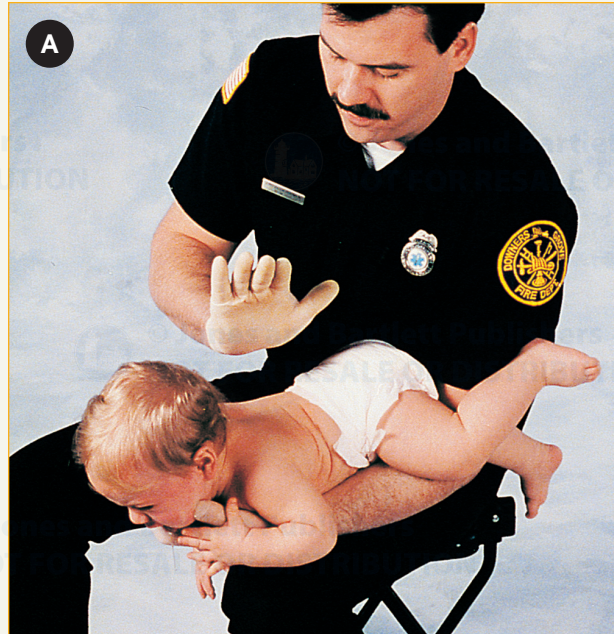

Figure 39-17 **A.** Deliver five quick back slaps between the shoulder blades, using the heel of your hand. **B.** Give five quick chest thrusts on the sternum at a slightly slower rate than you would give for CPR.

Rescue Breathing in Adults

Once you open the airway, check for breathing by placing your ear about 1" above the patient's nose and mouth; listen carefully for sounds of breathing. Turn your head so that you can watch for movement of the patient's chest and abdomen (Figure 39-18). This is called the look, listen, and feel technique. You know that the patient is

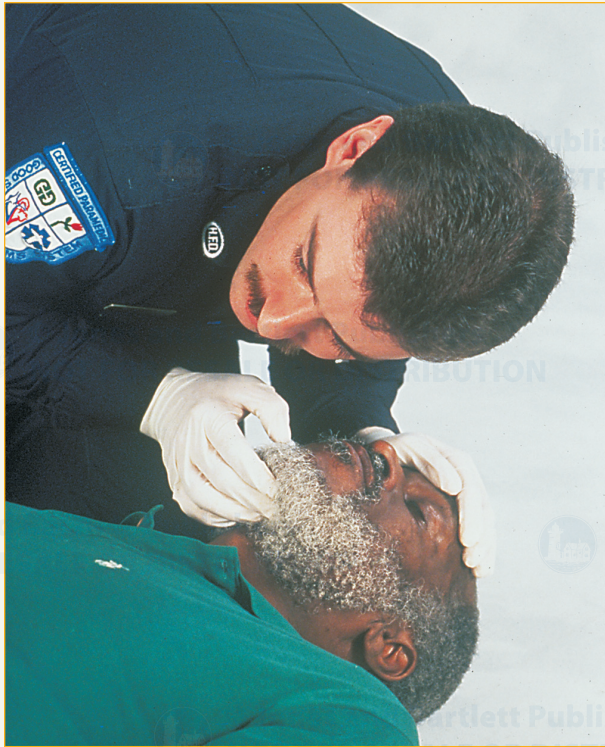


Figure 39-18 Look, listen, and feel for signs of breathing.

breathing if you see the chest and abdomen rise and fall and, more important, if you feel and hear air move during exhalation. With airway obstruction, there may be no movement of air, even though the chest and abdomen rise and fall as the patient tries to breathe. You may also have difficulty seeing movement of the chest and abdomen if the patient is fully clothed. Finally, you may see very little or no chest movement at all in some patients, particularly those with chronic lung disease. Therefore, if you do not feel any air movement as you look, listen, and feel, you must begin artificial ventilation. This evaluation should take at least 5 seconds but no more than 10 seconds.

A lack of oxygen in the blood, combined with too much carbon dioxide, is lethal. To correct this condition, you must provide slow, deliberate ventilations that last 1 second. This gentle, slow method of ventilating the patient minimizes the amount of air that is forced into the stomach.

Ventilation

Ventilations are now done routinely with barrier devices, such as masks. These devices feature a plastic barrier that covers the patient's mouth and nose and a one-way valve to prevent exposure to secretions and exhaled con-

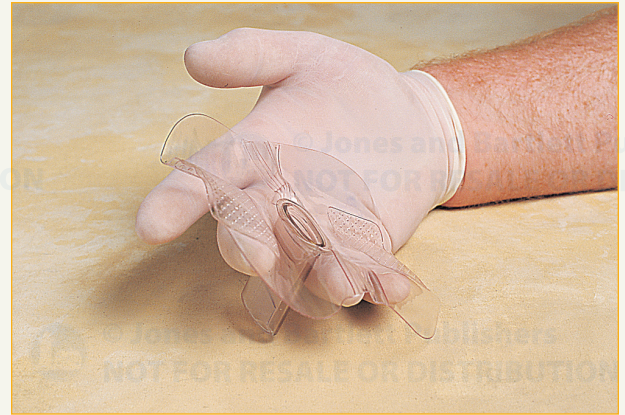

Figure 39-19 A barrier device is used in performing ventilation, because it prevents exposure to saliva, blood, and vomitus.

taminants **Figure 39-19 ▲**. Such devices also provide good infection control. Providing ventilation without a barrier device should be performed only in extreme conditions. The EMT-B should use devices that supply supplemental oxygen when possible. Devices that have an oxygen reservoir will provide higher percentages of oxygen to the patient. Regardless of whether you are ventilating the patient with or without supplemental oxygen, you should observe the chest for good rise to assess the effectiveness of your ventilation.

You should perform rescue breathing with a simple barrier device in an adult in the following way

Figure 39-20 ▼:

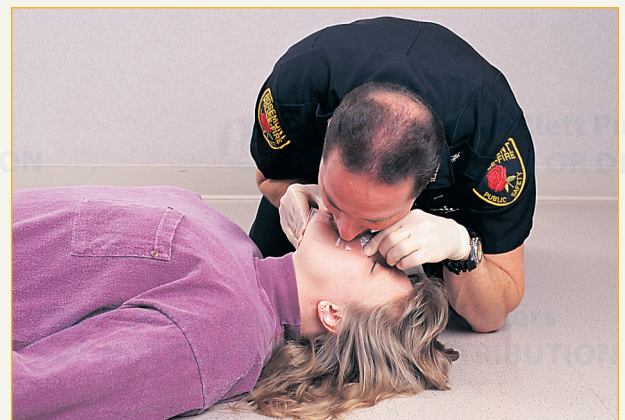


Figure 39-20 To perform ventilation, ensure that you make a tight seal with your mouth around the barrier device, and then give two slow rescue breaths, each lasting 1 second.

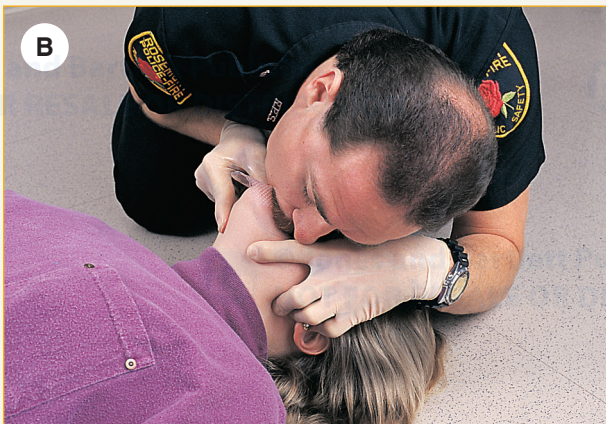
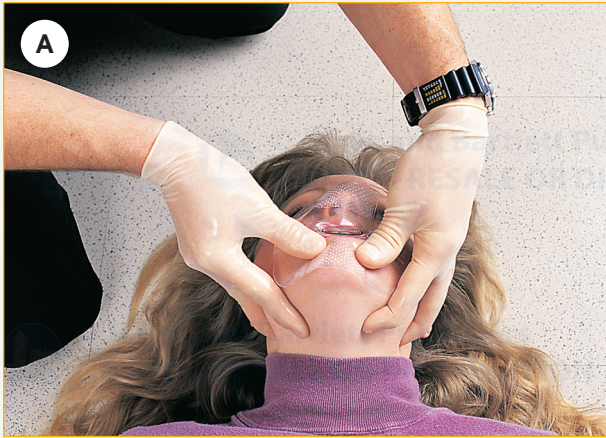
Figure 39-21 **A.** If you use the jaw-thrust maneuver to open the airway, keep the patient's mouth open with both thumbs as you move from above the patient's head to the side. **B.** Seal the nose by placing your cheek against the patient's nostrils.

1. Open the airway with the head tilt–chin lift maneuver (nontrauma patient).
2. Press on the forehead to maintain the backward tilt of the head. Pinch the patient's nostrils together with your thumb and index finger.
3. Depress the lower lip with the thumb of the hand that is lifting the chin. This will help to keep the patient's mouth open.
4. Open the patient's mouth widely, and place the barrier device over the patient's mouth and nose.
5. Take a deep breath, then make a tight seal with your mouth around the barrier device. Give two slow rescue breaths, each lasting 1 second followed by 10 to 12 breaths/min.
6. Remove your mouth, and allow the patient to exhale passively. Turn your head slightly to watch for movement of the patient's chest.

If you use the jaw-thrust maneuver to open the airway (that is, in suspected neck injury), you must move to the patient's side to provide ventilation. Positioning yourself at the patient's head is necessary to effectively stabilize the patient's head and provide ventilation at the same time. Keep the patient's mouth open with both thumbs, and seal the nose by placing your cheek against the patient's nostrils **Figure 39-21** ◀. Note that this maneuver is somewhat difficult; practice with a manikin will help you gain familiarity with this technique.

Ventilation Through a Stoma

Patients who have undergone surgical removal of the larynx often have a permanent tracheal stoma at the midline in the neck. A stoma is an opening that connects the trachea directly to the skin **Figure 39-22** ▼. Because it is at the midline, the stoma is the only opening that will move air into the patient's lungs; you should ignore any other openings. Patients with a stoma should be ven-

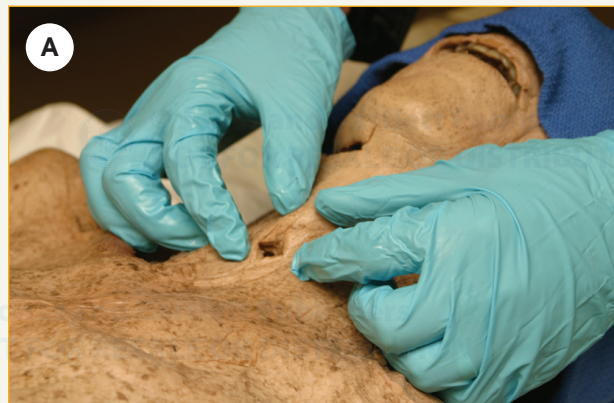

Figure 39-22 **A.** A stoma is an opening that connects the trachea directly to the skin. **B.** Use a BVM or pocket mask device to ventilate a patient with a stoma.

tilated with a BVM or pocket mask device, as described in Chapter 9.

Gastric Distention

Artificial ventilation may result in the stomach becoming filled with air, a condition called **gastric distention**. Although it occurs more easily in children, it also happens frequently in adults. Gastric distention is likely to occur if you blow too fast as you ventilate, if you give too much air, or if the patient's airway is not opened adequately. Therefore, it is important for you to give slow, gentle breaths. Such breaths are also more effective in ventilating the lungs. Serious inflation of the stomach is dangerous because it can cause the patient to vomit during CPR. It can also reduce lung volume by elevating the diaphragm.

If massive gastric distention interferes with adequate ventilation, you should contact medical control. Check the airway again, and reposition the patient's head, watch for rise and fall of the chest, and avoid giving forceful breaths. Medical control may order you to turn the patient on his or her side and provide gentle manual pressure to the abdomen to expel air from the stomach. Have suction readily available, and be prepared for copious amounts of vomitus. If gastric distention interferes with your ability to perform adequate artificial ventilation, it must be managed.

Recovery Position

The **recovery position** helps to maintain a clear airway in a patient with a decreased level of consciousness who has not had traumatic injuries and is breathing ade-



Figure 39-23 The recovery position is used to maintain an open airway in an adequately breathing patient with a decreased level of consciousness who has had no traumatic injuries. It allows vomitus, blood, and any other secretions to drain from the mouth.

quately on his or her own (Figure 39-23). It also allows vomitus to drain from the mouth. Roll the patient onto his or her side so that the head, shoulders, and torso move as a unit, without twisting. Then place the patient's hands under his or her cheek. Never place a patient who

Pediatric Needs

Children who are in respiratory distress are often struggling to breathe. As a result, they usually position themselves in a way that keeps the airway open enough for air to move. Let them stay in that position as long as breathing remains adequate. If you and your partner arrive at the scene and find that the infant or child is not breathing or has cyanosis, immediate management (that is, rescue breathing, supplemental oxygen) must be implemented. Consider requesting additional assistance, if available.

For infants, the preferred technique of rescue breathing is mouth-to-nose-and-mouth ventilation. With this technique, a seal must be made over the mouth and nose. Various masks and other barrier devices are recommended for this technique. If the patient is a large child for whom a tight seal cannot be made over both mouth and nose, you should provide mouth-to-mouth ventilation as you would for an adult.

Once you have made an airtight seal over the mouth, give two gentle breaths each lasting 1 second. These initial breaths will help you assess for airway obstruction and expand the lungs. Because the lungs of infants and children are much smaller than those of adults, you do not need to blow in a great amount of air. Limit the amount of air to that needed to cause the chest to rise.

Remember, too, that a child's airway is smaller than that of an adult. Therefore, there is greater resistance to airflow. As a result, you will need to use a bit more ventilatory pressure to inflate the lungs. You know you are giving the correct amount of air volume as soon as you see the chest rise. Infants and children should be ventilated once every 3 to 5 seconds, or 12 to 20 times per minute.

If air enters freely with your initial breaths and the chest rises, the airway is clear. You should then check the pulse. If air does not enter freely, you should check the airway for obstruction. Reposition the patient's head to open the airway, and attempt to give another breath. If air still does not enter freely, you must then take steps to relieve the obstruction.

has a suspected head or spinal injury in the recovery position because maintenance of spinal alignment in this position is not possible and further spinal injury could result.

Adult CPR

Once you have arrived at the scene and determined that the patient is unresponsive and not breathing, you must position the patient and begin rescue breathing. After you begin rescue breathing, you must assess the patient's circulation.

Cardiac arrest is determined by the absence of a palpable pulse at the carotid artery. Feel for the carotid artery by locating the larynx at the front of the neck and then sliding two fingers toward one side. The pulse is felt in the groove between the larynx and the sternocleidomastoid muscle, with the pulp of the index and long fingers held side by side (Figure 39-24 ▼). Light pressure is sufficient to palpate the pulse. Check the pulse for at least 5 seconds but no longer than 10 seconds; if a pulse cannot be felt, begin CPR.

External Chest Compression

You can provide CPR by applying rhythmic pressure and relaxation to the lower half of the sternum. The heart is located slightly to the left of the middle of the chest between the sternum and the spine



Figure 39-24 Feel for the carotid artery by locating the larynx, then sliding two fingers toward one side. You can feel the pulse in the groove between the larynx and sternocleidomastoid muscle.

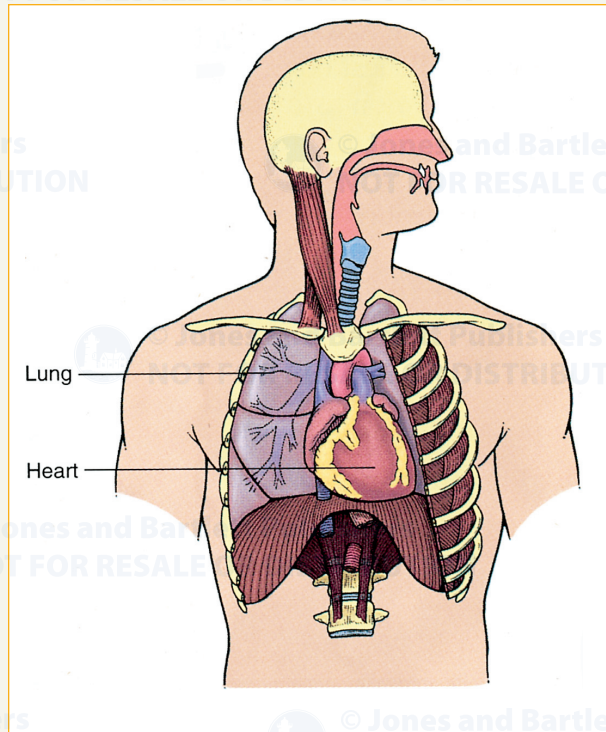


Figure 39-25 The heart lies slightly to the left of the middle of the chest between the sternum and spine.

(Figure 39-25 ▲). The blood that circulates through the lungs by chest compressions is likely to receive adequate oxygen to maintain life when accompanied by artificial ventilation. However, keep in mind that, at its best, external chest compression provides only one third of the blood that is normally pumped by the heart, so it is very important to do it properly.

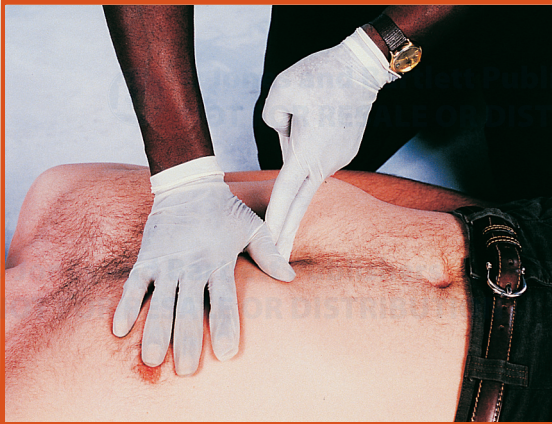
The patient must be placed on a firm, flat surface, in a supine position. The head should not be elevated at a level above the heart because this will further reduce blood flow to the brain. The surface can be the ground, the floor, or a backboard on a stretcher. You cannot perform chest compressions adequately on a bed; therefore, a patient who is in bed should be moved to the floor or have a board placed under the back. Remember, too, that external chest compressions must always be accompanied by artificial ventilation.

Proper Hand Position

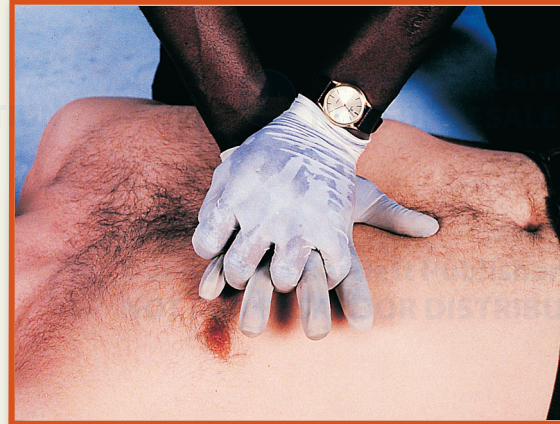Correct hand position is established by placing the heel of one hand on the sternum (center of the chest) between the patient's nipples (lower half of the sternum). Follow the steps in (Skill Drill 39-2 ►):

1. Place the heel of one hand on the sternum between the nipples (**Step 1**).

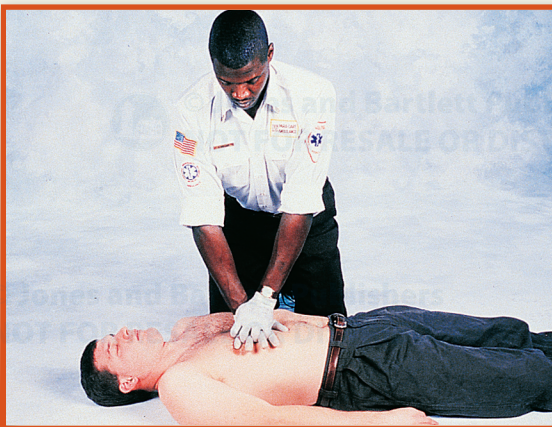
Performing Chest Compressions



1 Place the heel of one hand on the sternum between the nipples.



2 Place the heel of your other hand over the first hand.



3 With your arms straight, lock your elbows, and position your shoulders directly over your hands. Depress the sternum $1\frac{1}{2}$ " to 2", using a direct downward movement.

2. Place the heel of your other hand over the first hand (**Step 2**).
3. With your arms straight, lock your elbows, and position your shoulders directly over your hands. Depress the sternum $1\frac{1}{2}$ " to 2", using direct downward movement and then rising gently upward. It is important that you allow the chest to return to its normal position. Your technique may be improved or made more comfortable if you interlock the fingers of your lower hand with the fingers of your upper hand; either way, your fingers should be kept off the patient's chest (**Step 3**).

Proper Compression Technique

Complications from chest compressions are rare but can include fractured ribs, a lacerated liver, or a fractured sternum. Although these injuries cannot be entirely avoided, you can minimize the chance that they will occur if you use good, smooth technique and proper hand placement.

Proper compressions begin by locking your elbows, with your arms straight, and positioning your shoulders directly over your hand so that the thrust of each compression is straight down on the sternum (**Figure 39-26**). Depress the sternum $1\frac{1}{2}$ " to 2" in an adult, avoiding a rocking motion and rising gently

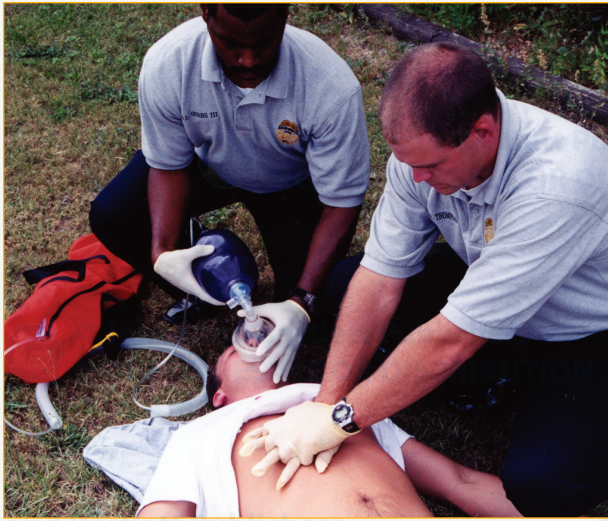

Figure 39-26 When performing CPR, be sure that your arms are in a locked position for adequate compressions, and maintain a good seal with the BVM device.

upward. This motion allows pressure to be delivered vertically down from your shoulders. Vertical downward pressure produces a compression that must be followed immediately by an equal period of relaxation. The ratio of time devoted to compression versus relaxation should be 1:1.

The actual motions must be smooth, rhythmic, and uninterrupted (Figure 39-27A). Short, jabbing compressions are not effective in producing artificial blood flow. Do not remove the heel of your hand from the patient's chest during relaxation, but make sure that you completely release pressure on the sternum so that it can return to its normal resting position between compressions (Figure 39-27B).

One-Rescuer Adult CPR

When you are doing CPR alone, you must give both artificial ventilations and chest compressions in a ratio of compressions to ventilations of 30:2. To perform one-rescuer adult CPR, follow the steps in

Skill Drill 39-3 ▶:

1. Determine unresponsiveness, and then call for additional help (Step 1).
2. Position the patient properly (supine), and open the airway using the method that matches your suspicion of spinal injury (Step 2).
3. Determine breathlessness by using the look, listen, and feel technique. If the patient is unconscious but breathing adequately, place him or her in the recovery position, and maintain the open airway (Step 3).
4. If the patient is not breathing, begin rescue breathing by delivering two breaths, for 1 second each (Step 4).
5. Determine pulselessness by checking the carotid pulse (Step 5). If you have an AED, apply it now.
6. If the patient is pulseless, begin compressions. Place your hands in the proper position for delivering external chest compressions, as described above.
7. Give 30 compressions at a rate of about 100/min for an adult. Each set of 30 compressions should take about 20 seconds. Using a rhythmic motion, apply pressure vertically from your shoulders down through both arms to depress the sternum $1\frac{1}{2}$ " to 2" in the adult, then rise up gently and fully. Count the compressions aloud (Step 6).
8. Open the airway, and then give two ventilations, each lasting 1 second.

You are the Provider

Part 4

Your partner applies an AED, and shocks the patient one time. You and your partner then begin immediate CPR. You secure the airway according to local protocols and provide artificial respirations via a BVM device attached to high-flow oxygen while your partner performs chest compressions.

7. For adult CPR, what is the appropriate rate and depth of compressions, and how can you help your partner in determining if the compressions are adequate?
8. If family members ask if the patient will be okay, what should you say?

EMT-I Tips

Performing CPR in the field is a different experience than practicing in the classroom and requires special preparations. You and your partner should drill in advance on how you will make the best use of your skills, equipment, and personnel available to assist. Besides improving patient care, practicing how to deploy equipment, assign roles, and move patients with fire crews who may respond to help you is also an excellent way to develop good working relations.

Geriatric Needs

Proper hand position and depth of compression, always important, take on added priority in older patients who are likely to have brittle bones and chest cartilage. There is no guarantee against causing injury to these tissues, and you must compress adequately to provide adequate perfusion of vital organs. Paying particular attention to your compression technique, however, will help reduce avoidable injuries.

9. Locate the proper position, and **begin another cycle** of chest compressions. Perform five cycles of compressions and ventilations.
10. After five cycles of compressions and ventilations, stop CPR and check for the return of a carotid pulse. If there is no change, resume CPR.

If the patient has a pulse, check for breathing. If the patient is not breathing or is breathing inadequately, provide rescue breathing. If the patient has a pulse, is breathing adequately, but remains unresponsive, place the patient in the recovery position and closely monitor the patient.

Two-Rescuer Adult CPR

You and your team should be able to perform both one-rescuer and two-rescuer CPR with ease. Two-rescuer CPR is always the first choice because it is less tiring for the rescuers and facilitates effective chest compressions. Once one-rescuer CPR is in progress, a second rescuer can be added very easily. He or she should enter the procedure after a cycle of 30 compressions and two ventilations. You should use airway adjuncts, such as mouth-to-mask ventilations, whenever possible. To perform two-rescuer adult CPR, follow the steps in

Skill Drill 39-4 ▶:

1. Moving to the head, **establish unresponsiveness** as your partner moves to the patient's side to be ready to deliver chest compressions (**Step 1**).
2. Position the patient to **open the airway** (**Step 2**).
3. **Check for breathing** by using the look, listen, and feel technique. If the patient is unconscious but breathing adequately, place him or her in the recovery position, and maintain the open airway (**Step 3**).
4. If the patient is not breathing, **begin rescue breathing** by delivering two breaths, for 1 second each (**Step 4**).

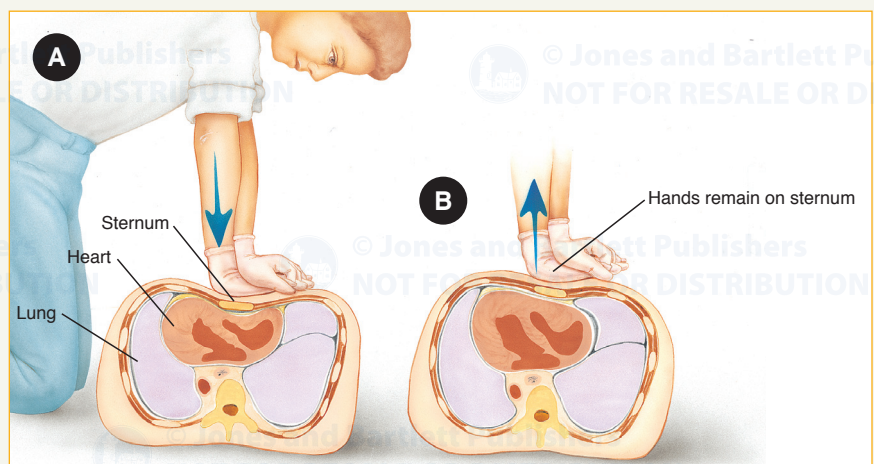
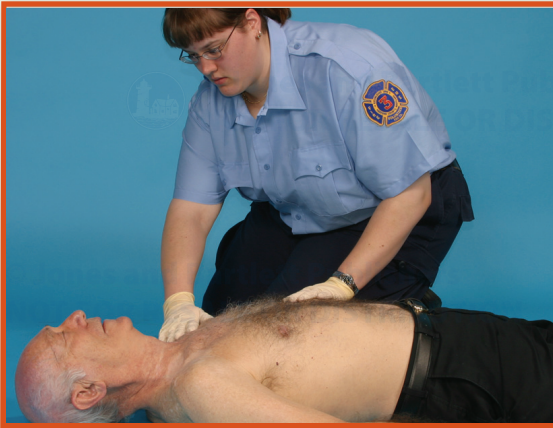

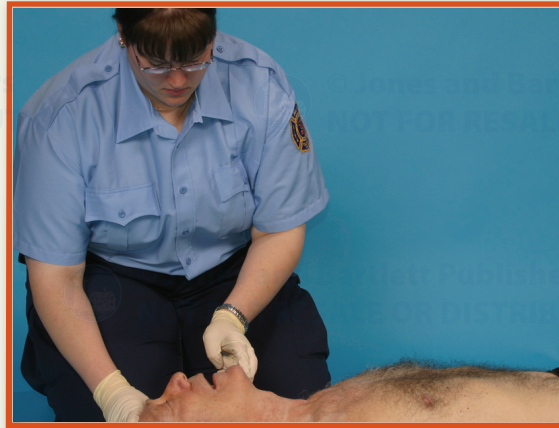Figure 39-27 A. Compression and relaxation should be rhythmic and of equal duration. B. Pressure on the sternum must be released so that it can return to its normal resting position between compressions. However, do not remove the heel of your hand from the sternum.

Performing One-Rescuer Adult CPR

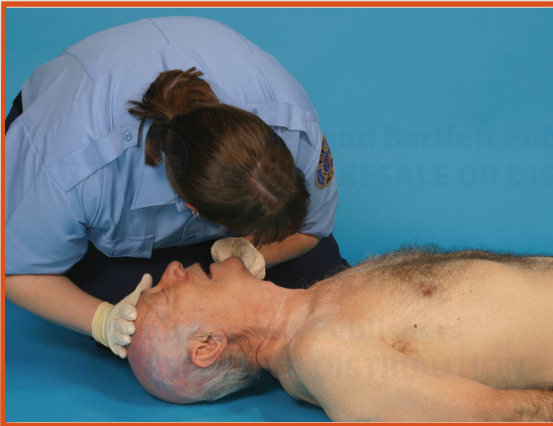39-3



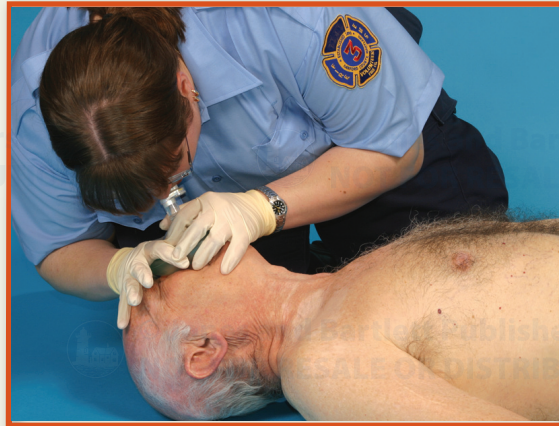- 1** Establish unresponsiveness, and call for help.



- 2** Open the airway.



- 3** Look, listen, and feel for breathing. If the patient is breathing adequately, place in the recovery position and monitor.

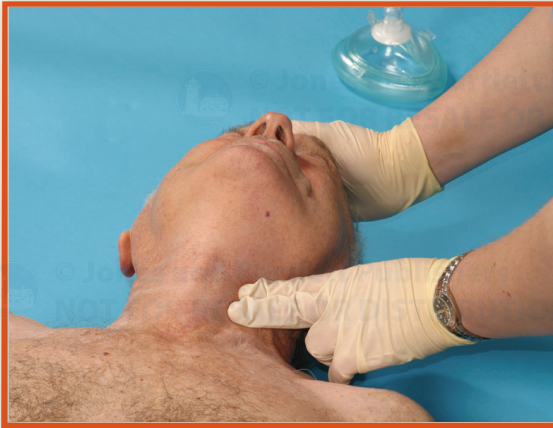

- 4** If not breathing, give two breaths of 1 second each.

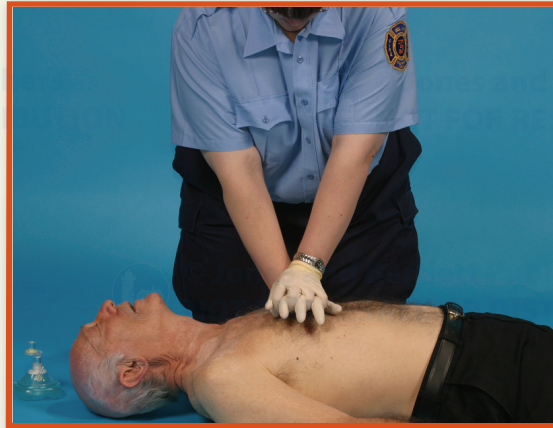- 5.** Determine pulselessness by checking the carotid pulse (**Step 5**). If the patient has no pulse and an AED is available, apply it now.
- 6.** Begin chest compressions at a compression to ventilation ratio of 30:2 (**Step 6**). Once the airway is secured (intubated) rescuers should no longer deliver cycles of CPR. Chest compressions should be delivered continuously (100/min) and rescue breaths delivered at a rate of 8 to 10 breaths/min.
- 7.** After five cycles of CPR, the rescuer providing compressions should be replaced. If there is a third rescuer available, have them position themselves at the chest opposite the compressor. Make the switch when both rescuers are ready, keep-

ing the switch time to as little as possible (no more than 5 to 10 seconds). If only two rescuers are available, make the switch mid-cycle during compressions to allow less delay during the switch to ventilations.

- 8.** Check for a pulse every 2 minutes. Pulse checks should last no more than 10 seconds. If there is no pulse, continue CPR beginning with compressions. If the patient has a pulse, check for breathing. If the patient is not breathing, provide ventilations. If the patient has a pulse, is breathing, but remains unresponsive, place the patient in the recovery position and closely monitor the patient.



5 Check for carotid pulse.



- 6** If no pulse is found, apply your AED. If there is no AED, place your hands in the proper position for chest compressions.
- Give 30 compressions at about 100/min.
 - Open the airway, and give two ventilations of 1 second each.
 - Perform five cycles of chest compressions and ventilations.
 - Stop CPR, and check for return of the carotid pulse.
 - Depending on the patient's condition, continue CPR, continue rescue breathing only, or place the patient in the recovery position and monitor breathing and pulse.

Switching Positions

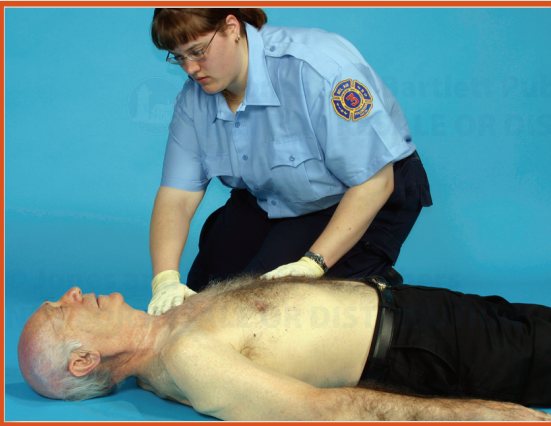Switching rescuers during CPR is beneficial to the quality of CPR administered to the patient. After 2 minutes of CPR, the rescuer providing compressions will begin to tire and compression quality will begin to suffer. It is therefore recommended to switch the rescuer doing compressions every 2 minutes. If there are only two rescuers, the rescuers will switch positions. If additional rescuers are available, rotating the rescuer providing compressions every 2 minutes is required. During switches, every effort should be made to minimize the time that no compressions are being administered. This

should be approximately 5 seconds but no more than 10 seconds of a break in between the compression cycle.

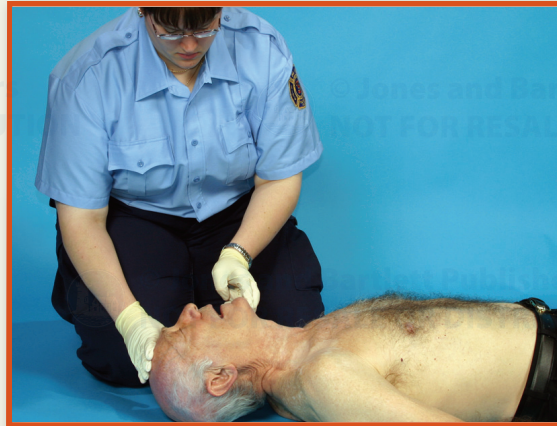The switch can be accomplished by the two rescuers knowing what each other will do. Rescuer one will begin another cycle of 30 compressions while rescuer two moves to the opposite side of the chest and moves into position to begin compressions. During the cycle, rescuer one will stop compressing and rescuer two will begin, continuing until 30 compressions have completed. Rescuer one will then deliver two ventilations and the CPR cycles will continue as needed.

Performing Two-Rescuer Adult CPR

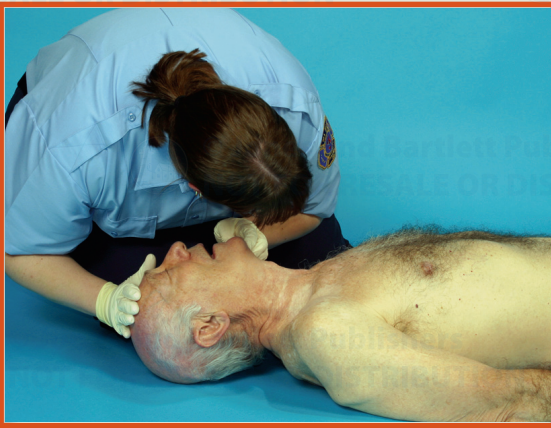39-4



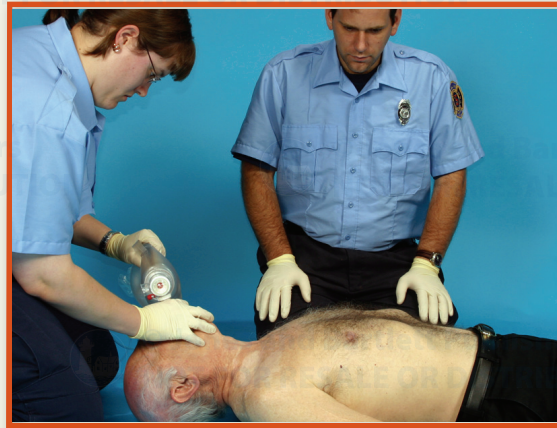- 1** Establish unresponsiveness and take positions.



- 2** Open the airway.



- 3** Look, listen, and feel for breathing. If the patient is breathing adequately, place in the recovery position and monitor.



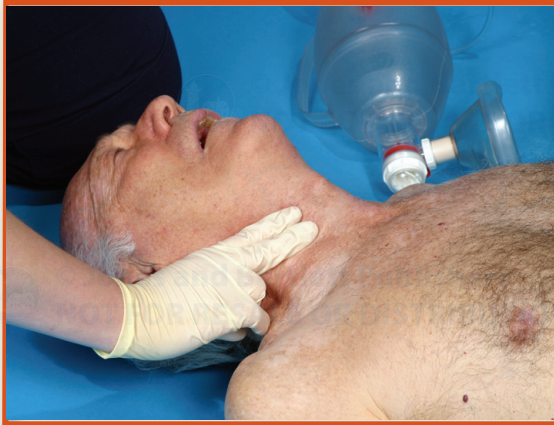- 4** If the patient is not breathing, give two breaths of 1 second each.

You are the Provider

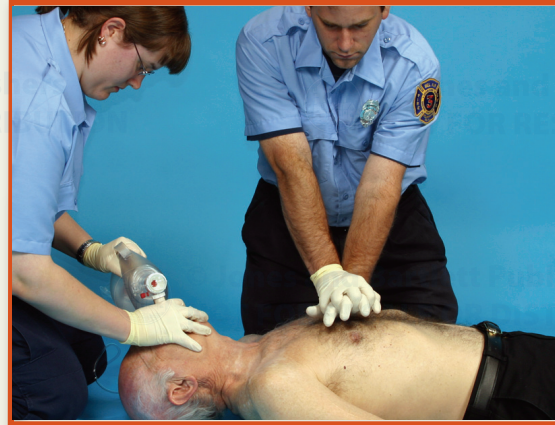Part 5

Volunteer fire fighters now arrive to assist you. They place the patient onto a backboard (to facilitate moving him) and transfer him to the gurney. You continue CPR en route to the hospital without any changes in the patient's condition. Although a pulse is regained in the emergency department, the patient later dies.

9. What are important considerations to make involving the needs of both responders and the patient's family?
10. What should be done after every major call such as this one?



- 5** Check for a carotid pulse. If no pulse is felt in 10 seconds, begin CPR.



- 6** If there is no pulse but an AED is available, apply it now. If no AED is available, begin chest compressions at about 100/min (30 compressions to two ventilations).
After every five cycles, switch rescuer positions in order to minimize fatigue. Keep switch time to 5 to 10 seconds.
Depending on patient condition, continue CPR, continue ventilations only, or place in recovery position.

Infant and Child CPR

In most instances, cardiac arrest in infants and children follows respiratory arrest, which triggers hypoxia and ischemia of the heart. Children consume oxygen two to three times as rapidly as adults. Therefore, you must first focus on opening an airway and providing artificial ventilation. Often, this will be enough to allow the child to resume spontaneous breathing and, thus, prevent cardiac arrest.

Once the airway is open and you have delivered two breaths, you need to assess circulation. As with an adult, you should first check for a palpable pulse in a large central artery. Absence of a palpable pulse in a major central artery means that you must begin external chest compressions. You can usually palpate the carotid pulse

in children older than 1 year, but it is difficult in infants, who have short and often fat necks. Therefore, in infants, palpate the brachial artery, which is located on the inner side of the arm, midway between the elbow and shoulder. Place your thumb on the outer surface of the arm between the elbow and shoulder. Then place the tips of your index and long fingers on the inside of the biceps, and press lightly toward the bone [Figure 39-28](#) ▶.

External Chest Compression

Most BLS techniques are the same for infants, small children, larger children, and adults. As with an adult, an infant or child must be lying on a hard surface for the best results. If you are holding an infant, the hard surface can be your forearm, with your palm supporting

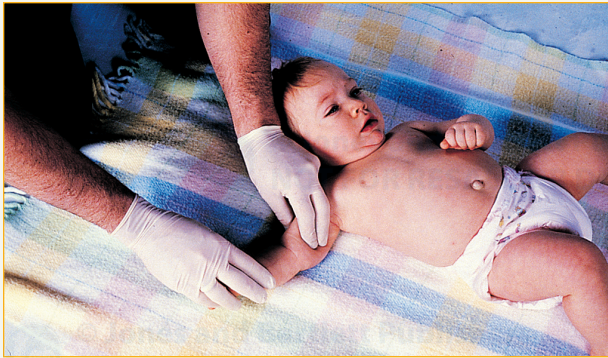


Figure 39-28 To assess circulation in an infant, palpate the brachial artery on the inner side of the arm, midway between the elbow and shoulder.

the infant's head. In this way, the infant's shoulders are elevated, and the head is slightly tilted back in a position that will keep the airway open. However, you must ensure that the infant's head is not higher than the rest of the body. The technique for chest compressions in infants and children differs because of a number of anatomic differences, including the position of the heart, the size of the chest, and the fragile organs of a child. The liver is relatively large, immediately under the right side of the diaphragm, and very fragile, especially in infants. The spleen, on the left, is much smaller and much more fragile in children than in adults. These organs are easily injured if you are not careful in performing chest compressions, so be sure that your hand position is correct before you begin.

Proper Hand Position and Compression Technique

The chest of an infant or child is smaller and more pliable than that of an adult; therefore, you should only use two fingers to compress the chest. In children, especially those older than 8 years of age, you can use the heel of one or both hands to compress the chest.

Infant CPR

In an infant, there are two methods for performing chest compressions: the two-finger technique and the two-thumb-encircling hands technique.

The two-finger technique is the preferred method for performing chest compressions if you are by yourself. Place two fingers of one hand over the lower half of the sternum, approximately 1 fingerbreadth below an imaginary line located between the nipples **Figure 39-29A** ▶. Compress the sternum approximately one third to one half the depth of the infant's chest. With

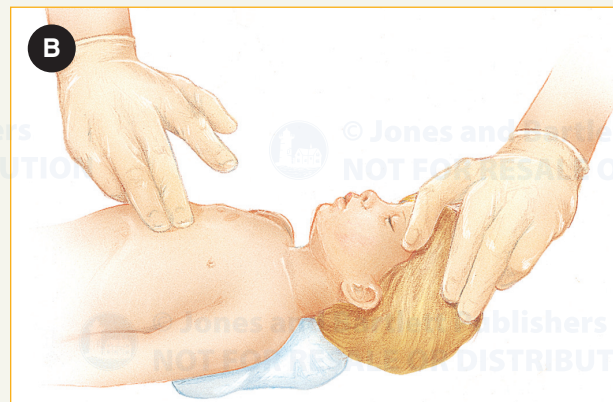
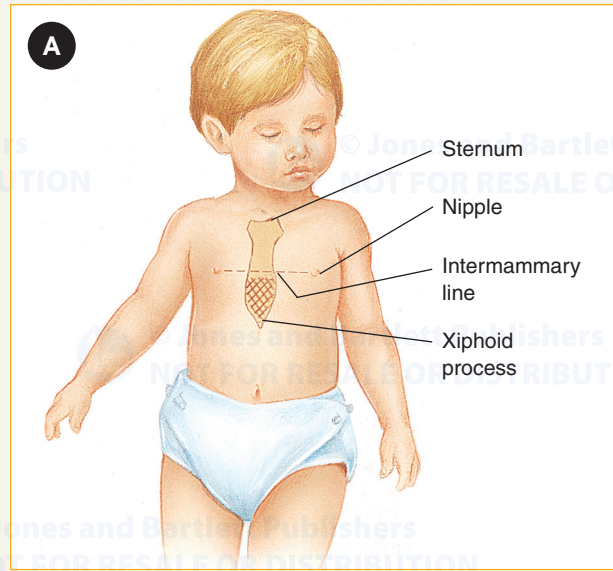


Figure 39-29 **A.** The proper location for chest compressions in an infant is in the midline, 1 fingerbreadth below an imaginary line drawn between the nipples at the sternum. **B.** With two fingers, compress the sternum approximately one third to one half the depth of the infant's chest. Perform compressions at a rate of approximately 100/min.

two fingers, perform compressions at a rate of at least 100/min **Figure 39-29B** ▲. Finger position is important in order to avoid compressing the xiphoid process.

The two-thumb-encircling hands technique is the preferred method for performing two-rescuer infant CPR, when physically feasible **Figure 39-30** ▶. Place both thumbs side by side over the lower half of the infant's sternum, approximately 1 fingerbreadth below an imaginary line located between the nipples. Ensure that the thumbs do not compress on or near the xiphoid process. In very small infants, you may need to overlap your thumbs. Encircle the infant's chest and support the infant's back with the fingers of both hands. With your hands encircling the chest, use both thumbs to depress the sternum approximately one third to one half the

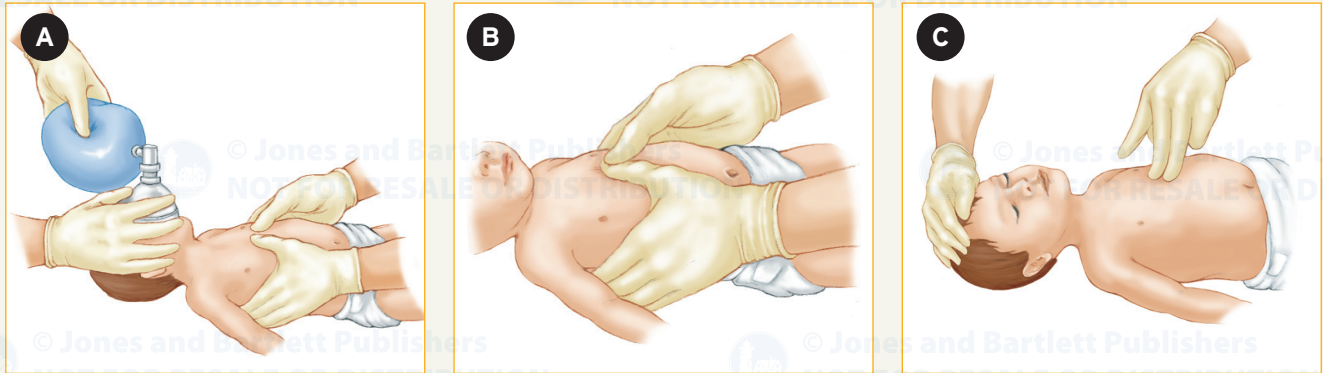


Figure 39-30 **A.** Place both thumbs side by side over the lower half of the infant's sternum, approximately 1 fingerbreadth below an imaginary line located between the nipples. **B.** In very small infants, you may need to overlap your thumbs. **C.** In larger infants, you may use the two-finger technique.

depth of the infant's chest. Perform compressions at a rate of at least 100/min. After 15 compressions, pause briefly for the second rescuer to deliver two ventilations. Compressions and ventilations should be coordinated to avoid simultaneous delivery and ensure adequate ventilation and chest expansion, especially when the infant's airway has not been definitively protected (intubated).

After each compression, release pressure from the sternum without removing your fingers (or thumbs) from the patient's chest. Use smooth, rhythmic motions to deliver compressions, as with adult CPR.

When performing one-rescuer CPR on an infant on a hard surface (for example, the ground, a table), make sure that the hand closest to the head remains on the infant's forehead during chest compressions. Your other hand may remain on the chest as you give rescue breathing. If the chest does not rise, remove the hand that is on the patient's chest, and reposition the airway using the appropriate maneuver. Then relocate the proper anatomic landmark and return the compression hand to the chest.

Child CPR

For a child older than 1 year, the way in which you deliver chest compressions differs. You will need to use more force with a child than with an infant, compressing the sternum with the heel of one or both hands to a depth that is approximately one third to one half the depth of the child's chest. Perform compressions at a rate of about 100/min. Your other hand (if only using one hand to compress the chest) should be used to maintain the child's head position so that you can provide rescue breathing without repositioning the head

Figure 39-31 ▶ Compressions should be delivered in

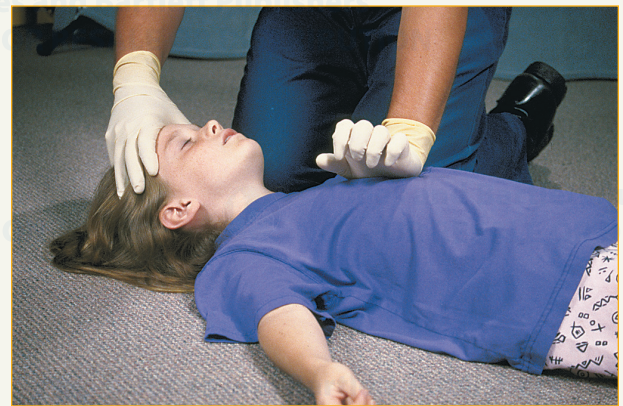

Figure 39-31 When performing chest compressions on a child, use the heel of one hand to compress the sternum to a depth that is approximately one third to one half the depth of the child's chest. Perform compressions at a rate of about 100/min. If you are using only one hand to compress the chest, the other hand should remain on the child's head to maintain an open airway.

a smooth, rhythmic manner in which the chest returns to its resting position after each compression.

As with an adult, external chest compressions on a child or infant must be coordinated with ventilations. The ratio of compression to ventilation for children is 30:2 for one-rescuer and 15:2 for two-rescuer CPR.

Reassess the child after five cycles (about 2 minutes) of CPR and every 2 minutes thereafter. Pulse checks, which should take at least 5 seconds but no more than

EMT-I Tips

Integrate the AED into the CPR sequence for children over 1 year of age.

10 seconds, should be done at the carotid or femoral artery. If no pulse is felt after 10 seconds, continue CPR.

Switching rescuer positions is the same for children as it is for adults, after every 5 cycles (about 2 minutes) of CPR. The best time to switch positions is when you reassess the child for breathing and circulation.

Interrupting CPR

CPR is an important holding action that provides minimal circulation and ventilation until the patient can receive definitive care in the form of defibrillation or

further care at the hospital. No matter how well it is performed, however, CPR is rarely enough to save a patient's life.

Try not to interrupt CPR for more than a few seconds, except when it is absolutely necessary. For example, if you have to move a patient up or down stairs, you should continue CPR until you arrive at the head or foot of the stairs, interrupt CPR at an agreed-upon signal, and move quickly to the next level where you can resume CPR. Do not move the patient until all transport arrangements are made so that your interruptions of CPR can be kept to a minimum.

You are the Provider

1. Given the initial nature of the call, what would be a good idea?

Immediately requesting more resources is always a good idea whenever the nature of the call sounds serious. Ideally, ALS should be simultaneously dispatched, but if paramedics are not available in your area, request extra hands to assist with patient transfer, equipment retrieval, etc. Use available resources, including fire fighters or other trained personnel.

2. After the dispatcher notifies you that CPR is in progress, what should you do to prepare?

Beyond the memorization of protocols, before you arrive on scene you should review who will perform which functions. This avoids confusion on the scene and decreases the overall time to administer necessary therapies. It is also beneficial to notify the receiving hospital and/or medical control of the nature of the dispatch. Most hospitals appreciate being notified to enable the emergency department staff to prepare.

3. What is your first priority?

The safety of you and your crew is always the first priority. The presence of this animal constitutes a safety risk. You must ask the wife to remove the pet and put it in another area of the house for your protection and to prevent the interference of patient care procedures. After you address this safety issue, you must determine the patient's level of consciousness.

Summary

4. What information would you like to obtain from the patient's wife?

Some examples of questions include the following. Did she witness her husband's loss of consciousness? If not, when was the last time she saw her husband alert? Was he complaining of anything before he lost consciousness? What is his medical background and does he take any medications? Does he have a DNR? (Most family members will immediately inform you if there is a do not resuscitate order but may not be able to produce the paperwork. This can put you in a very tough predicament, but be prepared for this situation as it can be common.) Did she perform CPR?

5. Why should you move the patient, and what should you do if you cannot?

In order to effectively execute CPR (adequately compressing the heart between the sternum and spine), it must be performed on a hard surface. If the patient is too large or you cannot move him for some other reason, you must place a hard surface (such as a CPR board or similar item) underneath his torso. If CPR was done prior to your arrival with the patient on a soft surface, this will be important to know and document.

You are the Provider *continued*

Summary

6. What do you do to manage his airway, and what should be the next step your partner performs?

You cannot perform artificial respirations with his airway full of emesis. Therefore, you must aggressively clear his airway (preferably using a portable electric suction unit). You then need to secure his airway according to your local protocols. The EMT-I scope of practice includes the use of PtLs, Combitubes, or LMAs. Some EMT-Is may intubate while others may not. At a minimum, an oral airway must be inserted to prevent the tongue from obstructing the airway, and cricoid pressure may then be applied to prevent or reduce aspiration. Regurgitation can be minimized by performing correct ventilations—not forcing air into the lungs either too much or too fast (air will follow the path of least resistance). Your partner should assess the patient for the presence of a pulse. If the patient has no pulse, the AED should be applied as quickly as possible.

7. For adult CPR, what is the appropriate rate and depth of compressions, and how can you help your partner in determining if the compressions are adequate?

Adult compressions should be at a rate of 100 times per minute at a depth of 1½" to 2". During CPR, you can assist your partner by feeling for a carotid pulse as each compression is performed. Depth of compressions can then be adjusted accordingly.

8. If family members ask if the patient will be okay, what should you say?

You should never lie or mislead the patient's friends or family members. Explain that you are doing all that you can for him, but that he is not breathing, his heart is not beating, and it is very serious. Giving them false hope will only make the situation more difficult should the patient not survive, and they will likely resent you for it.

9. What are important considerations to make involving the needs of responders and family?

Unfortunately, not every call results in a happy ending. For each minute that passes the patient's chances of survival decrease by 7 to 10%. When you factor in whether or not this was a witnessed/recognized arrest and the time it takes to access 9-1-1, to obtain the necessary information, to dispatch appropriate resources, and travel time, it's easy to understand why the national average for survival of sudden cardiac arrest in the prehospital setting is only about 5%. Early defibrillation is the key to patient survival. This is why public access defibrillation makes such a tremendous impact. Whenever possible, you should assist family members in their time of need. This can be as simple as offering to call friends or clergy members to help them, or answering their questions in an open and honest way. You should offer critical incident stress debriefing (CISD) for family members or bystanders who performed CPR. Don't leave them to deal with their feelings alone. Also, if there were new rescuers involved in helping or if there were unusual circumstances surrounding the call likely to bother seasoned providers, make sure that they receive CISD. Performing CPR for the first time as a new rescuer can be traumatic, especially if that patient does not survive.

10. What should be done after every major call such as this one?

Even seasoned providers can use constructive criticism to improve their skills and techniques. Every significant call should undergo a formal review for quality improvement or assurance. These reviews should involve all members on the call and other department personnel who did not respond but can benefit from reviewing the information. This should be performed in conjunction with the EMS coordinator and the program medical director. Reviewing calls is not about finding or placing blame, but about learning and striving to improve.

Prep Kit

Ready for Review

- Basic life support (BLS), such as CPR, is a noninvasive series of emergency lifesaving procedures that are carried out in order to treat airway obstruction, respiratory arrest, and cardiac arrest. Commonly known as cardiopulmonary resuscitation (CPR), it is a method of providing artificial ventilation and circulation.
- The effectiveness of BLS depends on prompt recognition of respiratory and/or cardiac arrest and the immediate initiation of treatment. You are expected to be able to recognize cardiac or respiratory arrest without difficulty and to quickly institute proper BLS measures.
- BLS can be given by one or two EMT-IIs or EMT-Bs, by first responders, or by alert, well-trained bystanders. It does not require any equipment; however, a barrier device should be used to perform rescue breathing.
- The basic principles of BLS are the same for infants, children, and adults. According to the American Heart Association (AHA), anyone younger than 1 year is considered an infant. A child is between 1 year of age and puberty (12 to 14 years of age). Adulthood is from onset of puberty and older.
- Several methods exist for opening the airway and providing rescue breathing. Each has specific applications for conscious or unconscious patients, with or without head or spinal injury. The head tilt-chin lift maneuver is effective for opening the airway of most patients. However, for patients who have suspected spinal injury, the jaw-thrust maneuver is indicated.
- Rescue breathing is done routinely with a barrier device, such as a mask, to provide infection control.
- Sometimes, rescue breathing causes excess air to be forced into the stomach. The resulting condition is called gastric distention. A patient with gastric distention may vomit during CPR. If this condition develops, you should continue to provide slow rescue breaths; however, if gastric distention is interfering with your ability to perform effective ventilation, medical control may order you to turn the patient on his or her side and apply gentle pressure to the abdomen to relieve the gastric distention. Be sure to have suction immediately available.
- If a patient begins breathing following rescue breathing, you should place the patient in the recovery position. This position helps to maintain a clear airway in a patient with a decreased level of consciousness who has not had traumatic injuries and is breathing adequately on his or her own.
- After you begin rescue breathing, you must assess the patient's circulation. If the patient has no pulse, you must provide artificial circulation by performing chest compressions at the rate and depth appropriate for the patient's age.
- If an AED is available, immediately attach it to the patient and provide defibrillation as indicated. The AED is indicated for patients in nontraumatic cardiac arrest who are over the age of 1 year. If using an AED on a child between 1 and 8 years of age, if available, you should use pediatric-sized pads and a dose-attenuating system (energy reducer).
- Remember that the patient must be on a firm, flat surface for chest compressions to be effective. Proper hand position and proper compression technique are essential for artificial circulation to be effective.
- CPR can be done with one or two rescuers. Two-rescuer CPR is always the first choice. When a rescuer is doing adult CPR alone or with another rescuer, the ratio of compressions to ventilations is 30:2.
- In infants and children, the ratio of compressions to ventilations is 30:2 if one rescuer is present and 15:2 if two rescuers are present. For one-rescuer infant CPR, compress the chest with the two-finger technique; the two thumb-encircling hands tech-

Technology

Interactivities

Vocabulary Explorer

Anatomy Review

Web Links

Online Review Manual

nique should be used for two-rescuer infant CPR. For child CPR, compress the chest with the heel of one or both hands, depending on the child's size. In infants and children, the chest should be compressed one-third to one-half the depth of the chest at a rate of 100/min.

- Remember that you should try not to interrupt CPR for more than a few seconds, except when it is absolutely necessary.
- Specific techniques must be used for removing foreign bodies that obstruct the airway. Obstruction may be caused by many things, including relaxation of the tongue in an unconscious patient (most common), vomited or regurgitated stomach contents, a blood clot, damaged tissue after an injury, dentures, or a foreign body in the airway. Recognition of the obstruction and prompt intervention are critical.
- The manual maneuvers recommended for removing a foreign body airway obstruction are the abdominal-thrust maneuver (Heimlich maneuver) and chest thrusts.
- In infants and children, the cause of airway obstruction may be infectious. Therefore, you should try to identify the cause of the obstruction as soon as possible. Infants and children with such infections need immediate transport to the hospital and will not benefit from attempts to relieve a foreign body airway obstruction.

Vital Vocabulary

abdominal-thrust maneuver The preferred method to dislodge and force food or other material from the throat of a choking victim; also called the Heimlich maneuver.

advanced life support (ALS) Advanced lifesaving procedures, such as cardiac monitoring, administration of intravenous fluids and medications, and use of advanced airway adjuncts.

basic life support (BLS) Noninvasive emergency lifesaving care that is used to treat airway obstruction, respiratory arrest, or cardiac arrest. Although the term "BLS" represents a wide variety of procedures performed by the EMT-I, in this chapter, it is used synonymously with CPR.

cardiopulmonary resuscitation (CPR) The combination of rescue breathing and chest compressions used to establish adequate ventilation and circulation in a patient who is not breathing and has no pulse.

gastric distention A condition in which air fills the stomach as a result of high volume and pressure or airway obstruction during artificial ventilation.

head tilt-chin lift maneuver A technique to open the airway that combines tilting back the forehead and lifting the chin.

jaw-thrust maneuver A technique to open the airway by placing the fingers behind the angles of the patient's lower jaw and forcefully moving the jaw forward; can be performed with or without head tilt.

recovery position A position that helps to maintain a clear airway in a patient with a decreased level of consciousness who has had no traumatic injuries and is breathing adequately on his or her own.

Assessment in Action

You are awakened one morning to the sound of pounding on your door. It is your neighbor's daughter. She screams for help. When you open the door she tells you that she can't wake her father up. She thinks he is dead.

You grab your kit and rush over to the house. In the bedroom you find your neighbor lying prone beside the bed. You roll him over and shout his name. He is unresponsive; 9-1-1 has already been called.

You open his airway and look, listen, and feel for breathing. There is none. With your pocket mask in place you give two breaths. You check for a pulse and it too is absent. You begin chest compressions. After five cycles of CPR you reassess and find there are still no signs of life. You continue CPR. Soon, your coworkers arrive in the ambulance. You continue CPR while they attach the AED to your neighbor. After assessment, no shock is advised. One of your coworkers takes over compressions for you and you continue to ventilate. As soon as possible, the other crewmembers move the patient to the ambulance and transport. You stay behind and comfort the daughter. Later, you drive her to the hospital where her father was taken. You learn they were unable to resuscitate him.

- What is the correct rate of compressions for this patient?
 - >100
 - 100
 - 80
 - 60
- There was no evidence of trauma noted in this case, so the airway should have been opened by what method?
 - Jaw thrust
 - Head tilt–chin lift
 - Keeping the head neutral and using the jaw lift
 - Head tilt–jaw thrust
- CPR must be initiated unless:
 - the patient is cold to the touch.
 - the patient's family says not to start.
 - rigor mortis is present.
 - there is no lividity.
- Once started, you must continue CPR unless:
 - there is no breathing.
 - the patient is transferred to another trained person.
 - you feel like there is no longer any hope.
 - the patient's family requests that you stop.
- You know that starting CPR as quickly as possible after the collapse is important because damage to brain tissue from lack of oxygen may occur within:
 - 4–6 minutes.
 - 6–8 minutes.
 - 8–10 minutes.
 - 30 minutes.
- The ratio of your initial compressions to ventilations on this patient were:
 - 2:30.
 - 1:5.
 - 2:5.
 - 30:2.

Points to Ponder

While treating your child to an ice cream sundae at the local diner, you hear someone scream for help. You turn around in time to see a 6-year-old boy clutching his hands to his throat. He is cyanotic and not making any sounds or coughs. You run up behind him and ask, "Are you choking?" He nods. You tell him you are going to help and move behind him. You get down on your knees and wrap your arms around his torso. You make a fist and place it between his umbilicus and xiphoid. You make several attempts to dislodge the object by abdominal thrusts. Soon, a small piece off of a toy pops out of his mouth. He is awake and breathing easier but now has some coughing. You tell his mother that he should still be evaluated by a doctor to be sure the toy did not do any internal damage. The ambulance crew arrives and you tell your buddies what happened. They congratulate you on a job well done and move the boy to the ambulance.

Issues: Recognizing the Need for Abdominal Thrusts in the Choking Patient, Recognizing the Signs of Choking, Realizing the Need for Further Evaluation